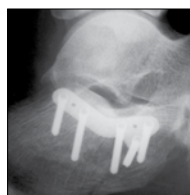

# ACUMED®

Innovative Solutions

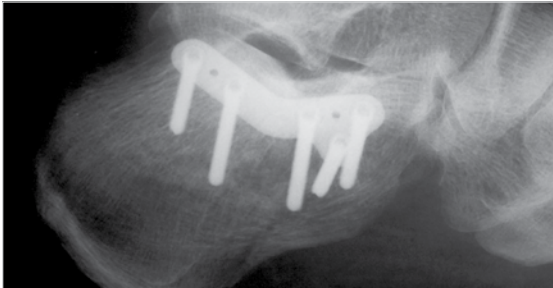


Calcaneal  
Plating System

# Calcaneal Plating System

*Acumed® is a global leader of innovative orthopaedic and medical solutions.*

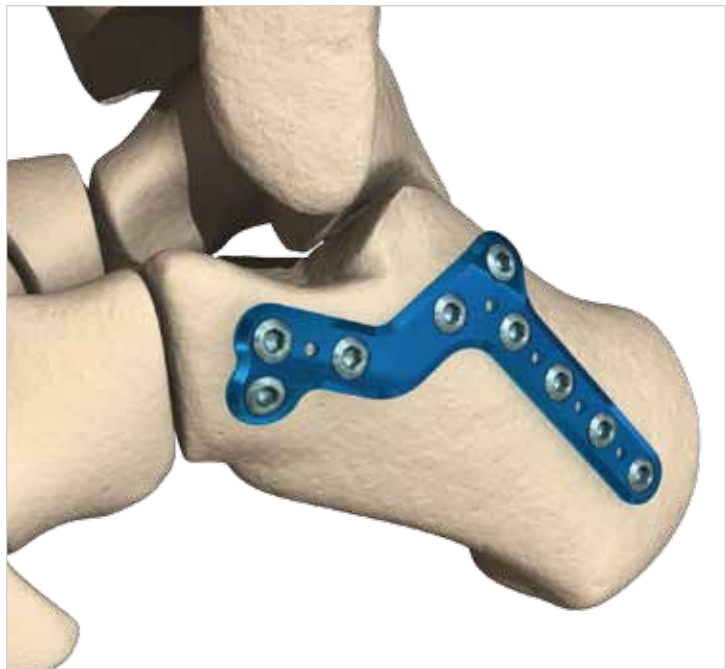
*We are dedicated to pioneering products, service methods and approaches that improve patient care.*



A New Standard of Treatment for Calcaneal Fractures.

Calcaneal fractures are the most common tarsal bone fractures and they are challenging to treat. The extensile lateral incision, which is today's most common approach, often results in nearly 30% of patients developing wound complications.<sup>1</sup>

With the expertise of Greg A. Horton, MD and Steven A. Herbst, MD, Acumed® has developed a family of calcaneal plates specifically designed for a minimally invasive approach using a sinus tarsi incision, a technique with less chance of wound complications when compared to extensile lateral surgeries.<sup>1</sup> While this kind of incision is not new, its use for calcaneal fractures in conjunction with the Acumed® MINI-Calc™ Plates is a revolutionary step forward in the treatment of calcaneal fractures.



The Acumed® Calcaneal Plating System is comprised of several MINI-Calc™ and lateral wall plates to meet a variety of procedural needs. To minimize soft tissue irritation while still providing a durable construct, the Calcaneal Plates were specifically designed to be low-profile and target the best quality bone in the calcaneus. Surgeons now have more options for this complex surgery.

## Contents

Introducing the System	2
System Features	3
Anterior Process Calcaneal Plate Technique	4
Posterior Tuberosity Calcaneal Plate Technique	6
Combo Calcaneal Plate Technique	8
Lateral Wall Calcaneal Plate Technique	10
Instrumentation and Screws	11
Ordering Information	12

## MINI-Calc™ Plates, Maximum Benefits

Acumed® MINI-Calc™ plates deliver a new level of performance, versatility, and reliability for calcaneal fracture surgery. Key advantages include:

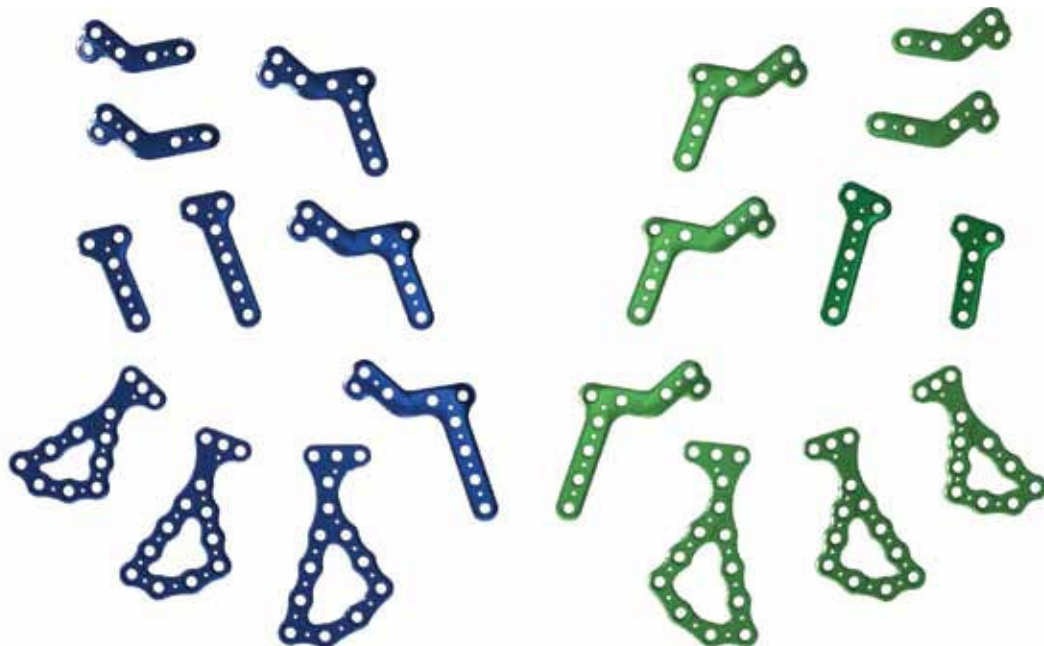
- **Approach-Specific Design.** Acumed® MINI-Calc™ plates are specifically designed to be inserted through a sinus tarsi incision. In addition to a potentially lower complication rate, this 5.0 cm incision provides direct visibility of the subtalar articular surface to aid in anatomic reduction of the fracture.
- **Fragment-Specific Options.** The Calcaneal Plating System offers a variety of plates to accommodate different fracture types. Whether comminution is present in the anterior process, through the posterior facet, in the posterior tuberosity, or any combination, plates are available to treat these fracture patterns.
- **Low-Profile.** The MINI-Calc™ Plates are 1.25 mm thick (.050") to minimize soft tissue irritation concerns.

In addition, Acumed® MINI-Calc™ plates are compatible with the Lower Extremity Modular System allowing surgeons to easily customize plates and instrumentation for each case.

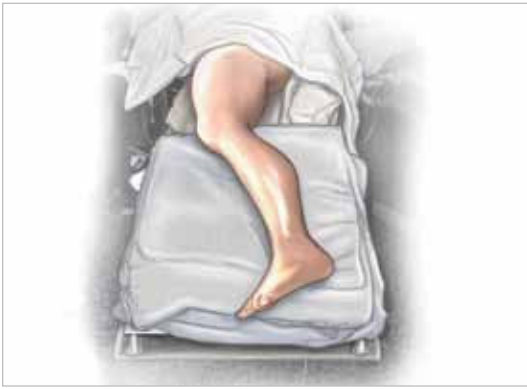

## Designed for Superior Performance

Acumed® MINI-Calc™ plates were designed to meet the complex demands of calcaneal fracture surgery.

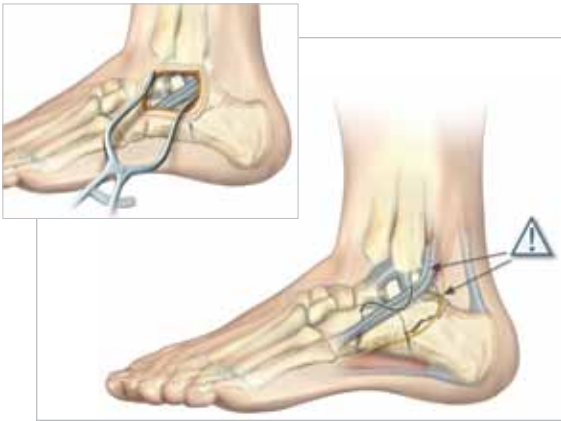


# Anterior Process Calcaneal Plate Technique



## 1 PATIENT POSITIONING

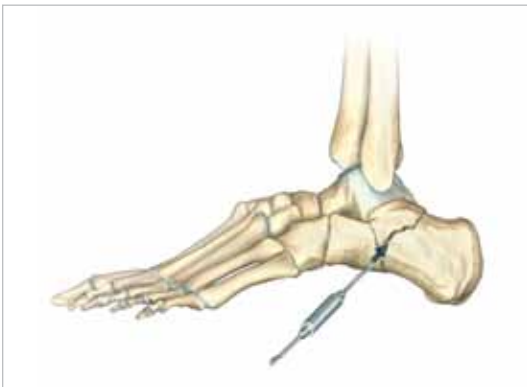- Obtain lateral and axial views of calcaneus, as well as CT views of the sagittal and coronal planes; compare to opposite extremity.
- Place patient in a lateral position with the operative extremity facing up.



## 2 EXPOSURE AND APPROACH

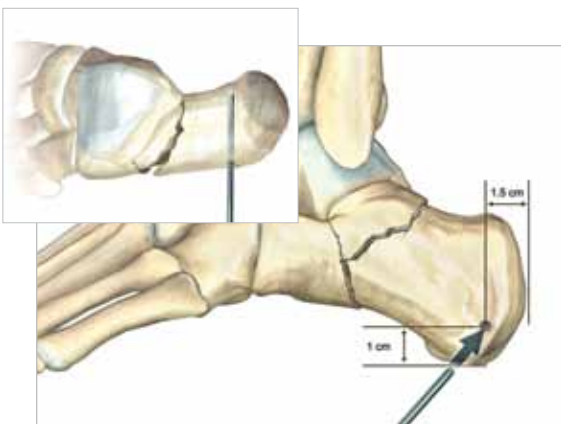
- Make a slightly S-shaped incision from base of the lateral malleolus to the calcaneocuboid joint. Carry dissection down to the subtalar joint.
- Retract peroneal tendons plantarly.
- To improve exposure, sharply take the calcaneofibular ligament.

Caution: Avoid peroneal tendon and sural nerve during dissection.



## 3 REDUCTION OF ARTICULAR SURFACE

- Use K-wires and Freer elevator to reduce posterior facet fragment to the sustentaculum tali.
- Ensure the Angle of Gissane is approximately 100° or equal to the opposite side.

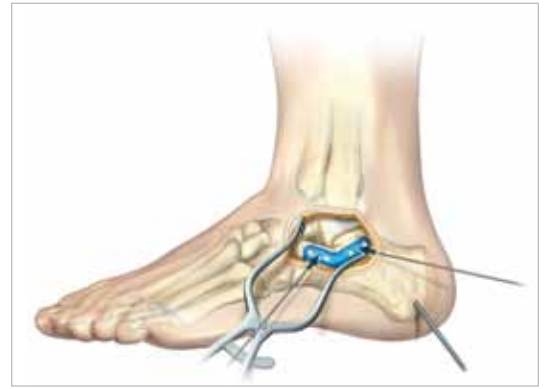

## 4 REDUCTION OF POSTERIOR TUBEROSITY

- Place Steinmann Pin lateral-to-medial in the approximate location shown.
- Pull tuberosity out of varus and back to length using the Steinmann Pin.
- Ensure Bohler's Angle is between 25°-40°.
- Verify reduction under fluoroscopy.

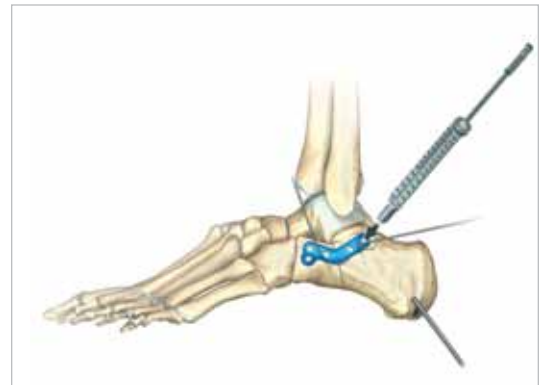## 5 PLATE INSERTION AND INITIAL FIXATION

- Insert plate through incision and confirm position under fluoroscopy.
- Use K-wires or plate tacks to provisionally fix the plate to the bone.



## 6 SCREW INSERTION

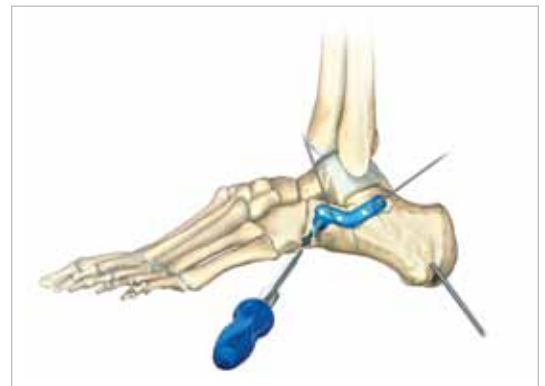- Thread locking drill guide (80-0384 or 80-0385) into the plate.
- Drill and measure for screws buttressing the posterior facet.
- Use yellow-banded drill (80-0386) for 2.7 mm screws and green-banded drill (80-0387) for 3.5 mm screws.



## 7 ANTERIOR PROCESS SCREW INSERTION

- Drill, measure, and insert screws on the anterior process.

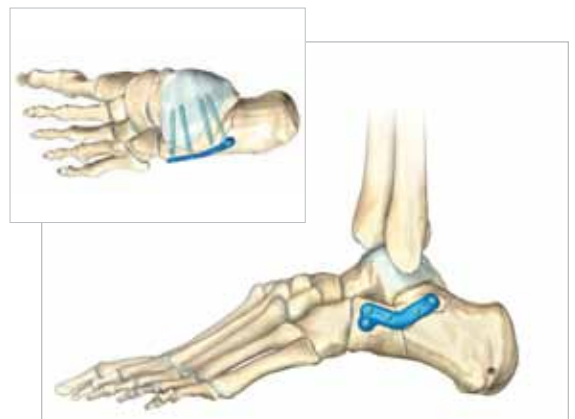Caution: Anterior screws may collide at lengths longer than 10 mm.



## 8 WOUND CLOSURE AND POSTOPERATIVE PROTOCOL

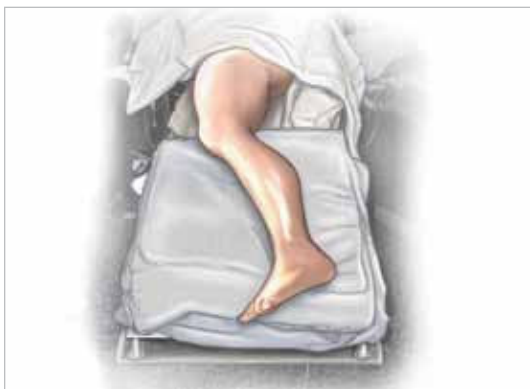- Verify reduction and screw placement under fluoroscopy.
- Close wound in layers.

When X-rays indicate adequate healing, full weight-bearing is allowed, based on surgeon judgment.



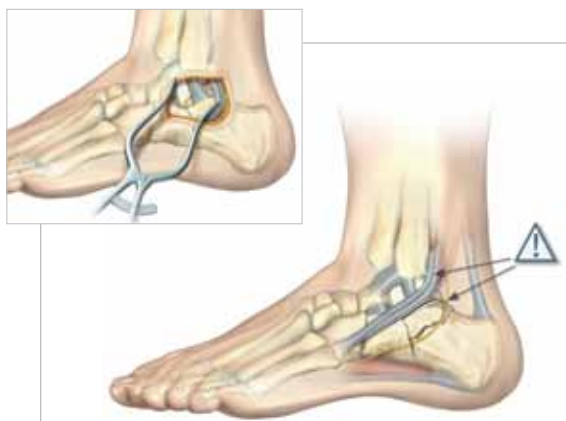

# Posterior Tuberosity Calcaneal Plate Technique



## 1 PATIENT POSITIONING

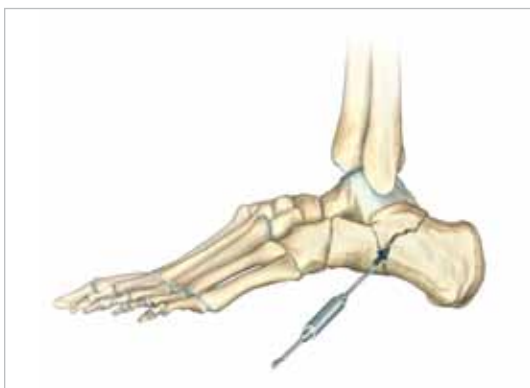- Obtain lateral and axial views of calcaneus, as well as CT views of the sagittal and coronal planes; compare to opposite extremity.
- Place patient in a lateral position with the operative extremity facing up.



## 2 EXPOSURE AND APPROACH

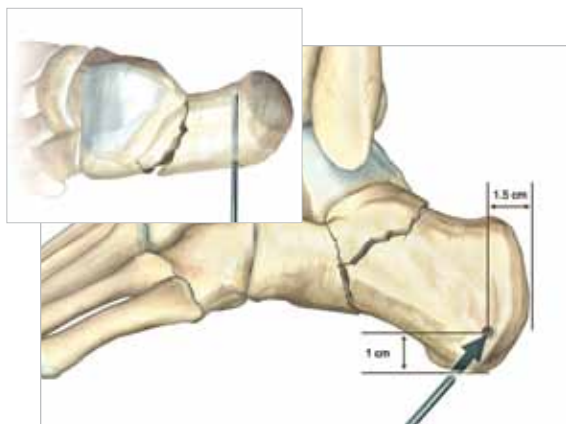
- Make incision directly inferior from the lateral malleolus and extend posterior approximately 3.0 cm. Carry dissection down to the calcaneus.
- To improve exposure, sharply take the calcaneofibular ligament.

Caution: Avoid peroneal tendon and sural nerve during dissection.



## 3 REDUCTION OF ARTICULAR SURFACE

- Use K-wires and Freer elevator to reduce posterior facet fragment to the sustentaculum tali.
- Ensure the Angle of Gissane is approximately 100° or equal to the opposite side.

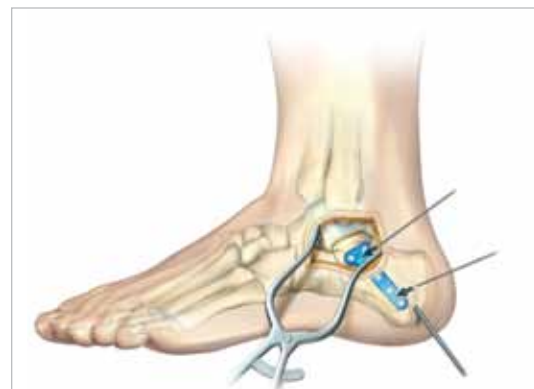

## 4 REDUCTION OF POSTERIOR TUBEROSITY

- Place Steinmann Pin lateral-to-medial in the approximate location shown.
- Pull tuberosity out of varus and back to length using the Steinmann Pin.
- Ensure Bohler's Angle is between 25°-40°.
- Verify reduction under fluoroscopy.

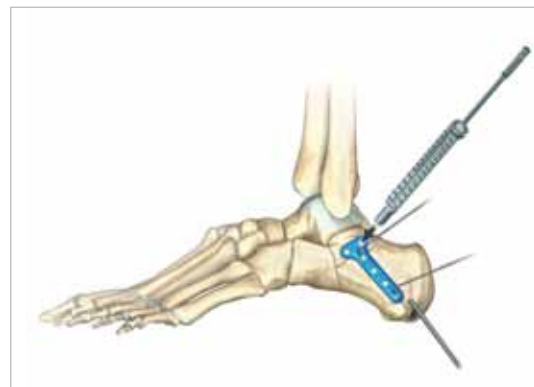
## 5 PLATE INSERTION AND INITIAL FIXATION

- Insert plate through incision and ensure position under fluoroscopy.
- Use K-wires or plate tacks to provisionally fix the plate to the bone.



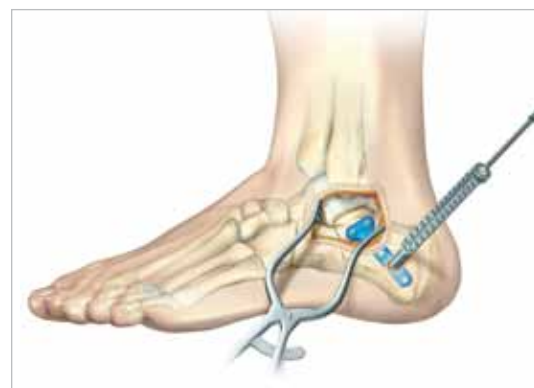## 6 SCREW INSERTION

- Thread locking drill guide (80-0384 or 80-0385) into plate.
- Drill and measure for screws buttressing the posterior facet.
- Use yellow-banded drill (80-0386) for 2.7 mm screws and green-banded drill (80-0387) for 3.5 mm screws.



## 7 POSTERIOR TUBEROSITY SCREW INSERTION

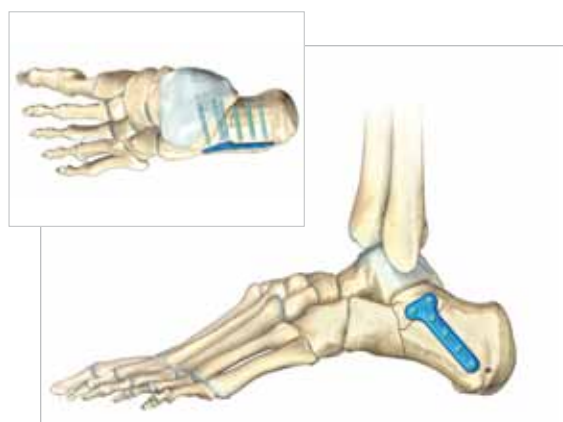- Use fluoroscopy to locate posterior screw holes percutaneously using a K-wire to verify location.
- Make stab incision over hole, drill, measure, and insert screws.



## 8 WOUND CLOSURE AND POSTOPERATIVE PROTOCOL

- Verify reduction and screw placement under fluoroscopy.
- Close wound in layers.

When X-rays indicate adequate healing, full weight-bearing is allowed, based on surgeon judgment.

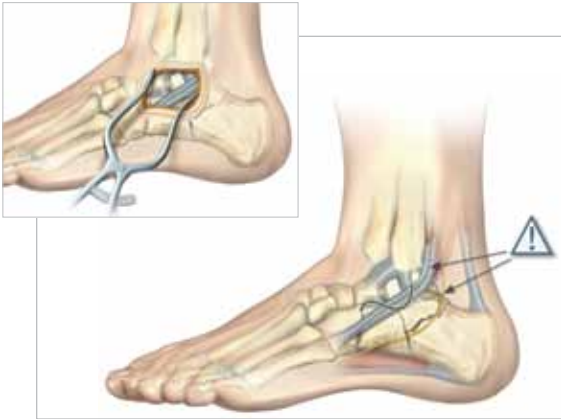

# Combo Calcaneal Plate Technique



## 1 PATIENT POSITIONING

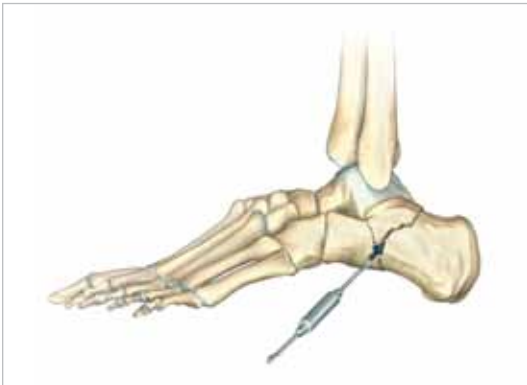- Obtain lateral and axial views of calcaneus, as well as CT views of the sagittal and coronal planes; compare to opposite extremity.
- Place patient in a lateral position with the operative extremity facing up.



## 2 EXPOSURE AND APPROACH

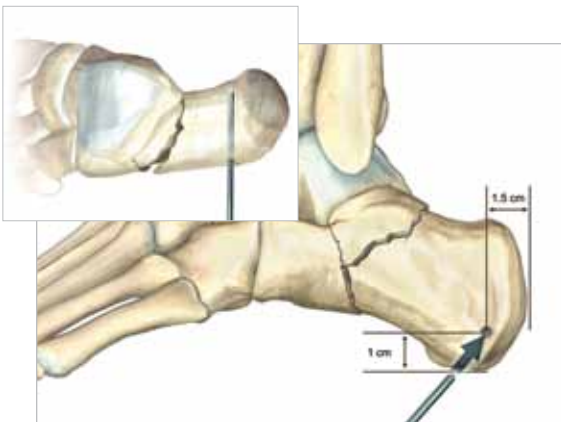
- Make a slightly S-shaped incision from base of the lateral malleolus to the calcaneocuboid joint. Carry dissection down to the subtalar joint.
- Retract peroneal tendons plantarly.
- To improve exposure, sharply take the calcaneofibular ligament.

Caution: Avoid peroneal tendon and sural nerve during dissection.



## 3 REDUCTION OF ARTICULAR SURFACE

- Use K-wires and Freer elevator to reduce posterior facet fragment to the sustentaculum tali.
- Ensure the Angle of Gissane is approximately 100° or equal to the opposite side.



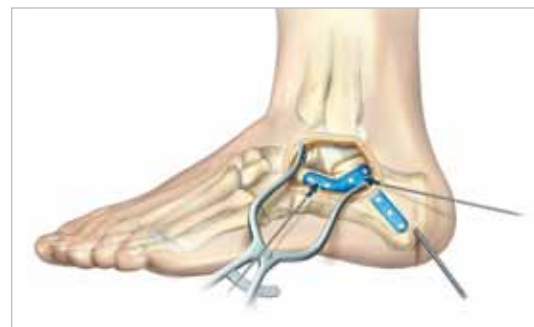## 4 REDUCTION OF POSTERIOR TUBEROSITY

- Place Steinmann Pin lateral-to-medial in the approximate location shown.
- Pull tuberosity out of varus and back to length using the Steinmann Pin.
- Ensure Bohler's Angle is between 25°-40°.
- Verify reduction under fluoroscopy.



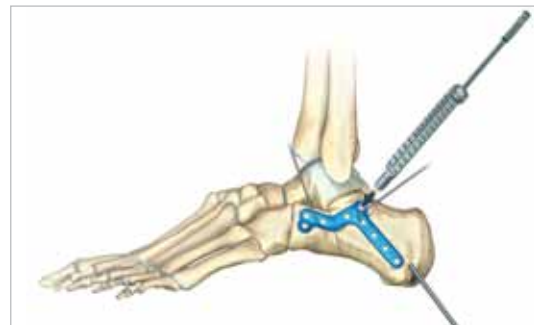
## 5 PLATE INSERTION AND INITIAL FIXATION

- Insert plate through incision and ensure position under fluoroscopy.
- Use K-wires or plate tacks to provisionally fix the plate to the bone.



## 6 SCREW INSERTION

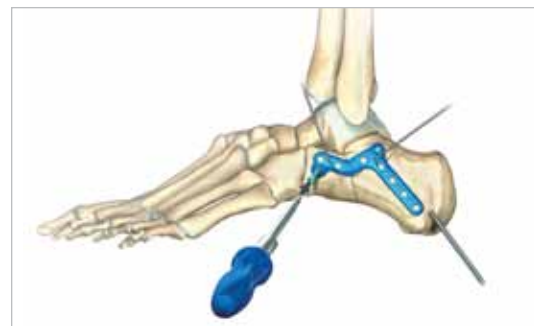
- Thread locking drill guide (80-0384 or 80-0385) into plate.
- Drill and measure for screws buttressing the posterior facet.
- Use yellow-banded drill (80-0386) for 2.7 mm screws and green-banded drill (80-0387) for 3.5 mm screws.



## 7 ANTERIOR PROCESS SCREW INSERTION

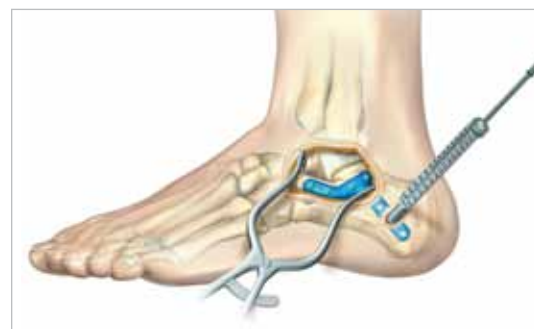- Drill, measure, and insert screws on the anterior process.

Caution: Anterior screws may collide at lengths longer than 10 mm.



## 8 POSTERIOR TUBEROSITY SCREW INSERTION

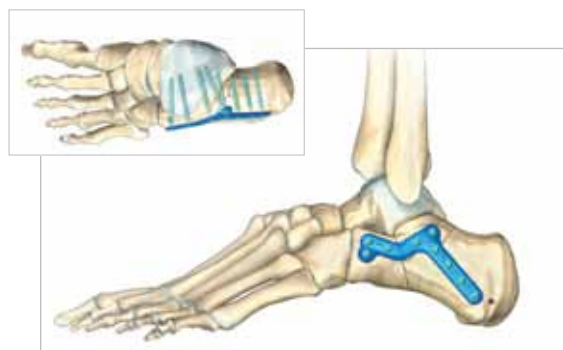
- Use fluoroscopy to locate posterior screw holes percutaneously using a K-wire to verify location.
- Make stab incision over hole, drill, measure, and insert screws.

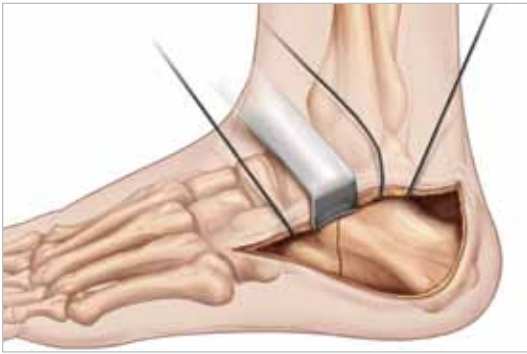

## 9 WOUND CLOSURE AND POSTOPERATIVE PROTOCOL

- Verify reduction and screw placement under fluoroscopy.
- Close wound in layers.

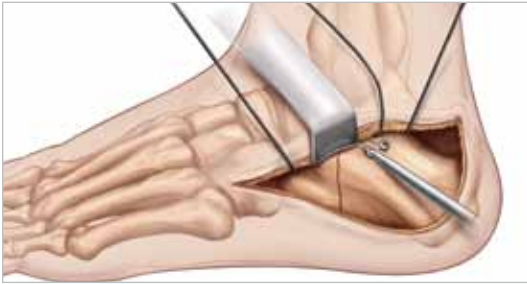When X-rays indicate adequate healing, full weight-bearing is allowed, based on surgeon judgment.





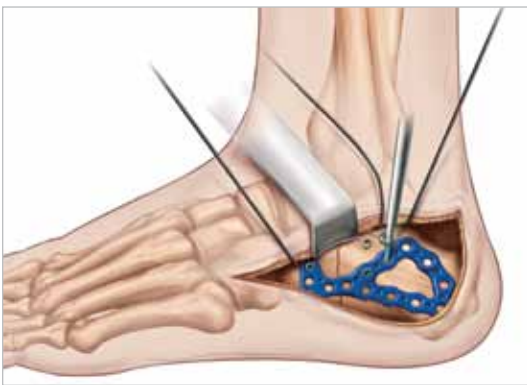## 1 EXPOSURE

The recommended surgical approach is lateral right-angled extensile approach (meticulous soft tissue handling is critical). Use blunt retractors only and use K-wire retraction once the full thickness lateral flap has been created. Reduction of the fracture typically involves the use of joysticks or Schanz screws placed into the calcaneal tuberosity to provide traction and manipulation of the tubor out of its angulated and translated position. The components of the calcaneus fracture, both extra-articular and intra-articular, are realigned and then held provisionally with multiple K-wires.



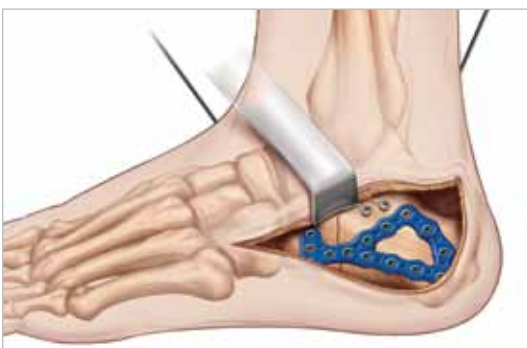## 2 POSTERIOR FACET SCREW PLACEMENT

We recommend the use of subchondral screws placed under the posterior facet to secure the posterior facet intra-articular portion of the calcaneus fracture. Typically, these are 2.7 or 3.5 mm cortical screws placed in an interfragmentary lag fashion. It is crucial that the screws remain extra-articular (do not penetrate the posterior facet). Careful evaluation, radiographically and clinically, should be used to confirm that the subchondral screws do not penetrate the posterior facet.



## 3 PLATE POSITIONING

The plate is applied to the lateral wall with the distal end placed just proximal (5-10 mm) to the calcaneocuboid joint in the anterior process. This can be adjusted based on fracture patterns. The triangular portion of the plate that supports the posterior facet typically sits just inferior to the interfragmentary screws. The plate should extend posteriorly enough to allow multiple screw engagement into the tuberosity. Typically, we prefer three screws to be placed into the tuberosity segment. The plate should be positioned and then held provisionally with K-wires. Both radiographic imaging and direct clinical inspection can confirm satisfactory position of the plate.



## 4 SCREW INSERTION

Screw placement is typically performed from the anterior process and extends posteriorly. 2.7 or 3.5 mm screws are used depending on surgeon preference. Initial screws should be place in a non-locking mode to secure the bone to the plate. Screws are then placed through the plate from the distal to proximal direction into the sustentaculum with the most posterior screws directed into the tuberosity. Locking screws are generally placed after the plate has been secured with multiple non-locking screws. Additional screws may be placed as needed to supplement the plate fixation.

## 5 CLOSURE AND POST-OP PROTOCOL

Wound closure is meticulously performed over a medium Hemovac drain with interrupted 4/0 nylon suture. For postoperative management, soft, bulky dressing incorporating plaster splints holding the foot in a neutral position are applied. The postoperative dressing is removed at three to seven days, and pending wound condition, subtalar range of motion is initiated in a removable device. Patients are kept non-weight bearing for 10 to 12 weeks.

## INSTRUMENTATION TO AID IN CALCANEAL FRACTURE REDUCTION:

- Steinmann pins
- Large Inge Retractor
- Periosteal elevator
- Series of Hohmann retractors
- Reduction clamps
- Freer Elevator



## SCREW OPTIONS:

- Up to 65 mm lengths for large patients
- 2.7 mm, 3.5 mm, and 4.0 mm diameter screws available
- Modular system design allows you to take what you need to the case. If you have a calcaneal fracture with an associated ankle fracture, the Lower Extremity Modular System will support both platters for your case.

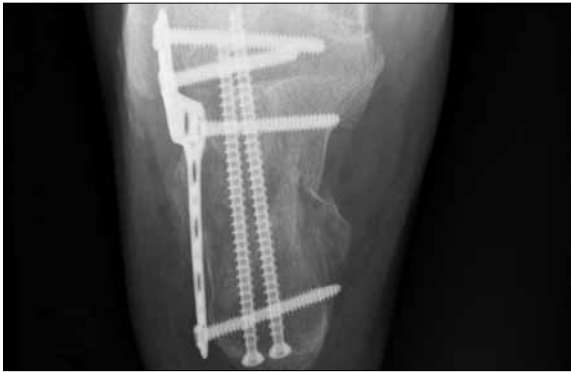
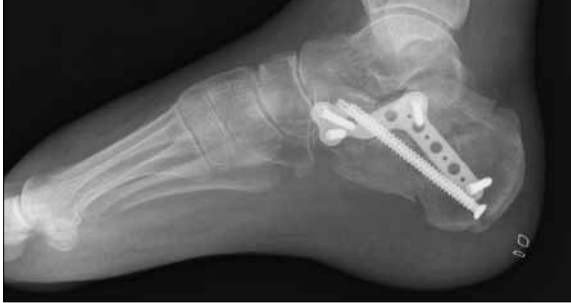
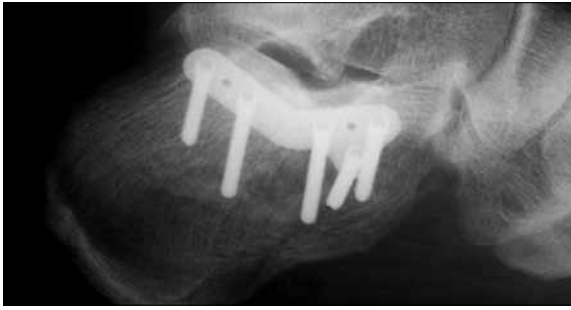## SCREW CONFIGURATIONS:

There are two configurations on the placement of the anterior-most screws depending on the patient's size and fracture pattern. A long bi-cortical screw and a short uni-cortical screw provide the stability necessary for fixing the anterior process. For optimal outcomes, place in one of the configurations as shown.



# Ordering Information



**ACUMED®**

5885 NW Cornelius Pass  
Road Hillsboro, OR 97124  
(888) 627-9957  
www.acumed.net

Distributed by:



HOSPITAL INNOVATIONS NV  
Mutsaardstraat 47 - B-9550 Herzele  
Tel.: +32 (0) 54 50 40 05  
Fax: +32 (0) 54 50 20 28  
info@hospitalinnovations.be  
www.hospitalinnovations.be

LEX00-05-A

Effective: 5/2011

© 2011 Acumed® LLC

## Calcaneal Plating System\*

Locking Calcaneal Plate, Small, Left	70-0022
Locking Calcaneal Plate, Small, Right	70-0023
Locking Calcaneal Plate, Medium, Left	70-0024
Locking Calcaneal Plate, Medium, Right	70-0025
Locking Calcaneal Plate, Large, Left	70-0026
Locking Calcaneal Plate, Large, Right	70-0027
Anterior Process Calcaneal Plate, Medium, Left	70-0386
Anterior Process Calcaneal Plate, Medium, Right	70-0387
Anterior Process Calcaneal Plate, Large, Left	70-0388
Anterior Process Calcaneal Plate, Large, Right	70-0389
Posterior Tuberosity Calcaneal Plate, 5 Hole, Left	70-0394
Posterior Tuberosity Calcaneal Plate, 5 Hole, Right	70-0395
Posterior Tuberosity Calcaneal Plate, 6 Hole, Left	70-0396
Posterior Tuberosity Calcaneal Plate, 6 Hole, Right	70-0397
Combo Calcaneal Plate, Medium, 8 Hole, Left	70-0400
Combo Calcaneal Plate, Medium, 8 Hole, Right	70-0401
Combo Calcaneal Plate, Large, 8 Hole, Left	70-0404
Combo Calcaneal Plate, Large, 8 Hole, Right	70-0405
Combo Calcaneal Plate, Large, 9 Hole, Left	70-0406
Combo Calcaneal Plate, Large, 9 Hole, Right	70-0407

## Instrumentation

4.0 mm Steinmann Pin, Smooth	35-0002
5.0 mm Steinmann Pin, Smooth	35-0003

## Tray Component

Calcaneal Plating System Tray	80-0744
Lower Extremity Tray Lid	80-0431

\*Plates are also available sterile-packed. Add -S to product number for sterile-packed product.

To learn more about the full line of Acumed® innovative surgical solutions, including the Calcaneal Plating System, please contact your local Acumed® Sales Representative or call 888-627-9957.

## REFERENCES

1. Schepers, T. (2011). "The sinus tarsi approach in displaced intra-articular calcaneal fractures: a systematic review." International Orthopaedics: 1-7.

These materials contain information about products that may or may not be available in any particular country or may be available under different trademarks in different countries. The products may be approved or cleared by governmental regulatory organizations for sale or use with different indications or restrictions in different countries. Products may not be approved for use in all countries. Nothing contained on these materials should be construed as a promotion or solicitation for any product or for the use of any product in a particular way which is not authorized under the laws and regulations of the country where the reader is located. Specific questions physicians may have about the availability and use of the products described on these materials should be directed to their particular local sales representative. Specific questions patients may have about the use of the products described in these materials or the appropriateness for their own conditions should be directed to their own physician.