

### Talonavicular Arthrodesis in a High Risk Patient

Christopher W. DiGiovanni, MD

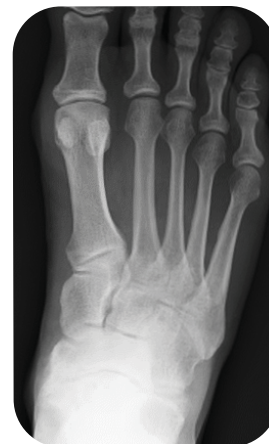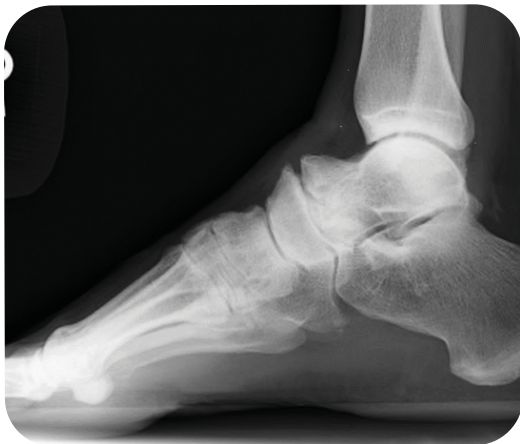Director, Brown University Orthopaedic Residency Program  
Professor and Chief, Foot and Ankle Service  
Department of Orthopaedic Surgery  
The Warren Alpert School of Medicine at Brown University  
Rhode Island Hospital, Providence, RI, USA

#### Clinical Presentation

This case involves a 50 year old male who presented with symptomatic post traumatic arthritis of his talonavicular joint. He was a steel worker, actively engaged in heavy physical labor which was becoming increasingly difficult. The patient had a PMH significant for smoking and alcoholism, and reported that he had incurred multiple fractures of his right foot in a fall over twenty years ago.

He recalled three operative procedures to treat these fractures and their sequelae in years past. Upon arrival to our office, the patient had already failed multiple attempts at non-operative management including a RICE protocol, NSAID medications, custom bracing, injections, and physical therapy.

#### Pre-op



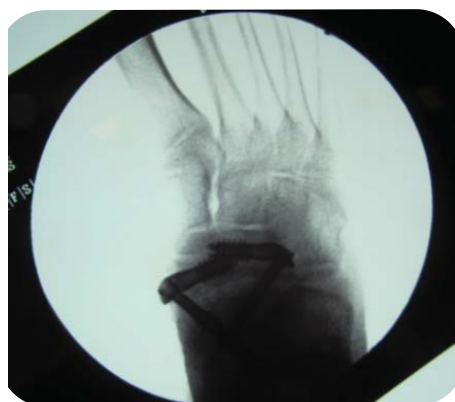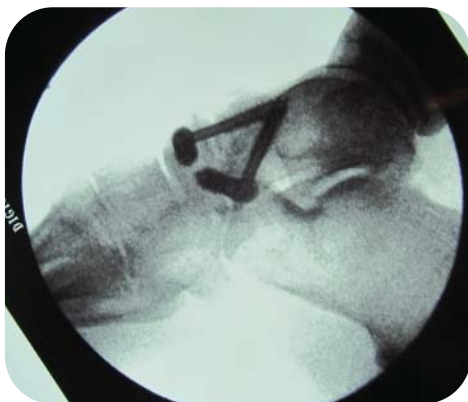
#### Surgical Management

Two IO FiX constructs, one placed medially and the other laterally, were utilized to provide rigid homogeneous compression across the talonavicular joint to maximize the potential for arthrodesis in this high risk patient. A medial utility approach was initially employed to takedown and prepare the TN joint for fusion. The medial IO FiX construct was easily placed through this same exposure. A mini-open lateral arthrotomy was then utilized to facilitate rapid placement of the second, laterally based construct.

## Clinical Case Review

As an initial step, the X-Post of both constructs was inserted across most of the navicular from their respectively staggered starting points. Each Lag Screw was then introduced through its appropriate X-Post and driven well into the talus. The positioning of these IOFiX constructs enabled significant axial compression, and avoided eccentric or edge loading, while maintaining rigidity in several planes. These posts act like giant lever arms ("IM washers") for their associated screws, through which the latter can generate remarkable stability. See the Extremity Medical IO FiX surgical technique for any further details on the procedure.

### Intra-op



### Outcome

This patient went on to a solid fusion despite early mobilization and numerous risk factors for nonunion. At this point, he is fully ambulatory, and effectively pain free at the surgical site. There exists no prominent or irritating hardware, as a result of the intraosseous nature of this fixation.

### Post-op

