

Calcaneal Osteotomy For Correction of Adult-Acquired Flatfoot Deformity

Shane Hollawell, DPM
Orthopaedic Institute of Central New Jersey

Clinical Presentation

This 45-year-old male presented with a history of medial ankle and foot pain. He had a progressive area of edema over the plantar medial arch with a noted decrease in the height of his foot. The patient described his foot as becoming “more flat” and a general feeling of weakness in the medial aspect of his foot and ankle. His foot condition had deteriorated over a number of years despite of conservative treatment that included orthotics, AFO, anti-inflammatory medication, and modification of activity and shoe wear.

Past medical history was unremarkable with no known drug allergies, and no current medications. Social History was negative for tobacco and alcohol use. The patient was a contractor by occupation

The pre-operative examination was consistent with a pes planovalgus foot type. There was a noted decrease in the longitudinal arch height isolated to the patient’s left foot, rearfoot valgus, and midfoot abduction. Both were flexible and reducible with manipulation. Edema was noted along the course of the posterior tibial tendon from its insertion into the navicular and just behind the medial malleolus. There was no forefoot deviation upon examination. The patient was unable to perform a single toe test on his left foot. X-Rays demonstrated a noted decrease in the calcaneal inclination angle, increased talar declination angle with abnormal Meary’s line, an uncovering of the talar head (talar escape), and midtarsal abduction. The patient was ultimately taken to the operating room to correct a progressive adult-acquired flatfoot deformity secondary to a long-standing posterior tibial tendon dysfunction.

Adult-Acquired Flatfoot Deformity: Overview

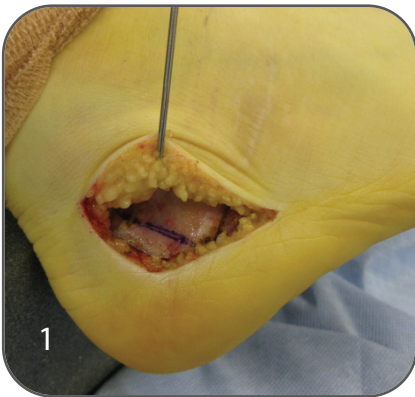
Adult-acquired flatfoot deformity entails inspection of conditions resulting in medial arch pain, swelling, and weakness. Although the etiology of the adult-acquired flatfoot deformity is not entirely clear, it is thought to be a multifactorial entity related to obesity, gender, age, activity, and systemic disease initially described as posterior tibial tendon failure. The deformity also encompasses a failure of the ligament complex of the medial arch. The posterior tibial tendon typically enlarges in both width and length and becomes insufficient. This dysfunction places increased stresses upon the spring ligament complex and leads to further instability to the talonavicular joint allowing for progressive arch flattening, calcaneal eversion, midtarsal abduction, increased pain, and functional limitations.

When pain and deformity persists in spite of conservative treatment and surgical intervention is indicated, the surgeon must address and correct all previous deformity through osseous realignment and soft tissue balancing when addressing an adult-acquired flatfoot deformity.

Surgical Management

Attention is typically first given to the Achilles tendon equinus contracture. Percutaneous lengthening was performed with a #11 scalpel blade in a three incision manner. Two incisions were placed posterior and medially to the Achilles tendon, a final incision was placed posterior and laterally in the midsubstance of the Achilles tendon. Upon completion of the percutaneous cusp, the foot was dorsiflexed and supinated to achieve adequate length to the tendon.

Once optimal dorsiflexion was achieved at the ankle, the percutaneous incisions were closed in a simple interrupted fashion (typically a probing or nylon suture). Attention was then given to the hindfoot valgus deformity as this deformity is often the most progressive plano deformities associated with an adult-acquired flatfoot condition.



The rearfoot valgus deformity is often corrected through Koutsogiannis calcaneal or medial slide osteotomy. A lateral semi-extensile curvilinear incision was made at the lateral wall of the calcaneus (1). The incision was placed inferior to the peroneal tendons in the sural nerve and then perpendicular to long axis of the calcaneus in the sagittal plane. The sural nerve and peroneal tendons were elevated off the lateral wall of the calcaneus. The lateral flap was then raised full thickness as one entire unit. The sural nerve and peroneal tendons were then retracted superiorly.

The osteotomy was then performed anterior to the tuber of the calcaneus and posterior to the posterior facet of the subtalar joint. I typically performed the osteotomy with a 140 microsagittal saw blade.

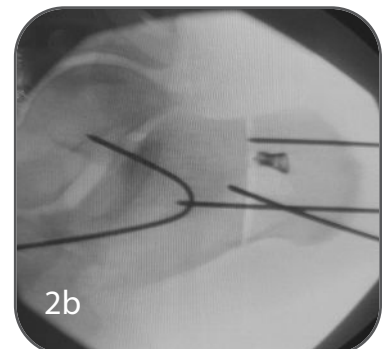
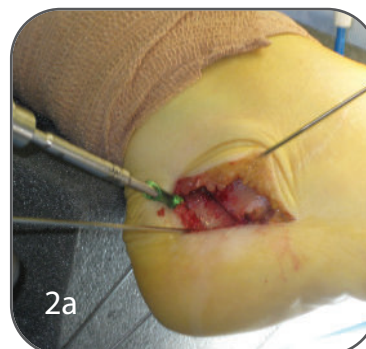
The position of osteotomy should be confirmed via intraoperative imaging by marking the osteotomy prior to initiating.

This is a through and through osteotomy from lateral to medial. The osteotomy is typically greenstick to the medial cortex to avoid damage to neurovascular bundle in the tarsal canal.

Once the medial slide (Koutsogiannis) osteotomy is completed, the calcaneus is transmitted medially and simultaneously plantar flexed to correct from the malalignment in both the frontal and sagittal planes respectively.

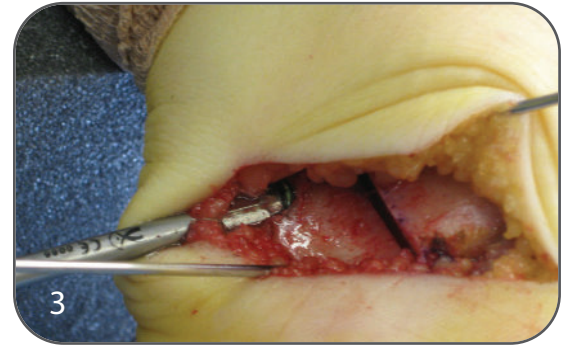
The osteotomy is typically stabilized with a posterior-anterior Steinman pin. A second Steinman pin is often utilized for second point of temporary fixation.

Once provisional fixation is in place, the X-Post™ of the Extremity Medical's IO FiX™ System was placed from lateral to medial (2a). The X-Post™, typically 20-25mm in length, is cannulated and placed over a 1.6mm K-wire perpendicular to the calcaneal osteotomy. The X-Post™ is placed even with the lateral calcaneal cortex of the posterior portion of the osteotomy (2b).



The system's clearing tool is utilized the X-Post™ to clear the bone that may interfere with lag screw fixation in a typical countersinking fashion (3).

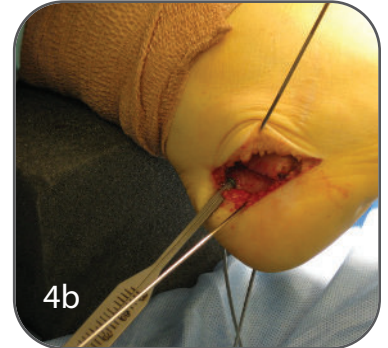
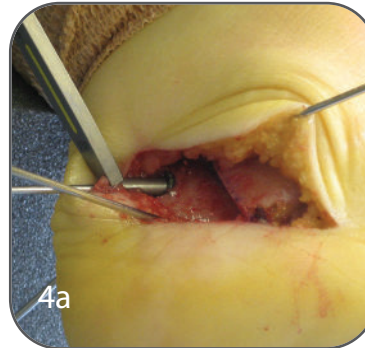
Once an adequate amount of bone has been cleared from the lip of the X-Post™ a drill guide is then seated within the X-Post™ (4a). This allows for the placement of an interfrag K-wire. This wire should be placed from posterior to anterior as perpendicular as possible to the osteotomy. Verify positioning and depth of the K-wire via fluoroscopy as this wire represents screw placement. The depth gauge is then used accordingly to measure lag screw length; typically a 30-40 mm x 4.0 mm interfrag screw is utilized (4b).



The IO FiX™ construct's cannulated screws are self-drilling and self tapping, so pre-drilling is up to the surgeon's discretion. The screw should be placed over the K-wire so that it remains centrally placed through the X-Post™ and crosses the osteotomy in a perpendicular fashion.

The lag screw is advanced by hand. As the head of the screw engages the X-Post™, the surgeon should feel an increase in torque on the driver (5a). The K-wire and two temporary Steinman pins should be removed prior to final tightening.

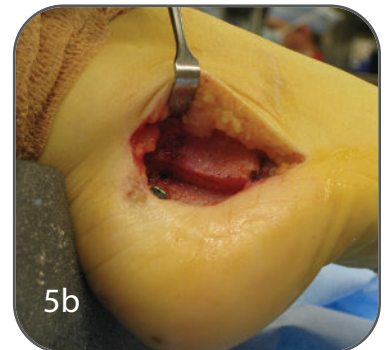
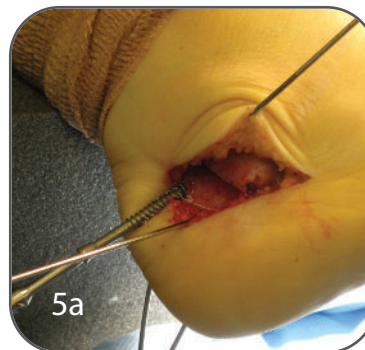
The screw is then advanced further (three-finger tightening is recommended for final seating of the screw) locking into the eyelet of the X-Post™ via a morse taper lock. This creates a fixed-angle device (similar in capacity to lock plating technology).



The interfrag screw and X-Post™ configuration provide excellent stability and compression across the medial calcaneal displacement osteotomy without any hardware prominence whatsoever (5b).

Any additional osteotomy correction can be performed accordingly to correct for any additional plano dominance abnormality.

The wound is then irrigated and closed in a layered fashion. The deeper tissue closed utilizing 2.0 Vicryl followed by subcutaneous closure with 3.0 Vicryl and skin approximation in an interrupted mattress or running fashion with either Prolene, nylon, or Monocryl suture.



Any tendon repair, soft tissue balancing procedure can be performed accordingly if determined to be necessary by the surgeon.

POSTOPERATIVE RESULTS/X-RAY FINDINGS

Lateral X-ray findings demonstrated an increased calcaneal inclination angle, elevated talar declination angle, and restored Meary's line (6).

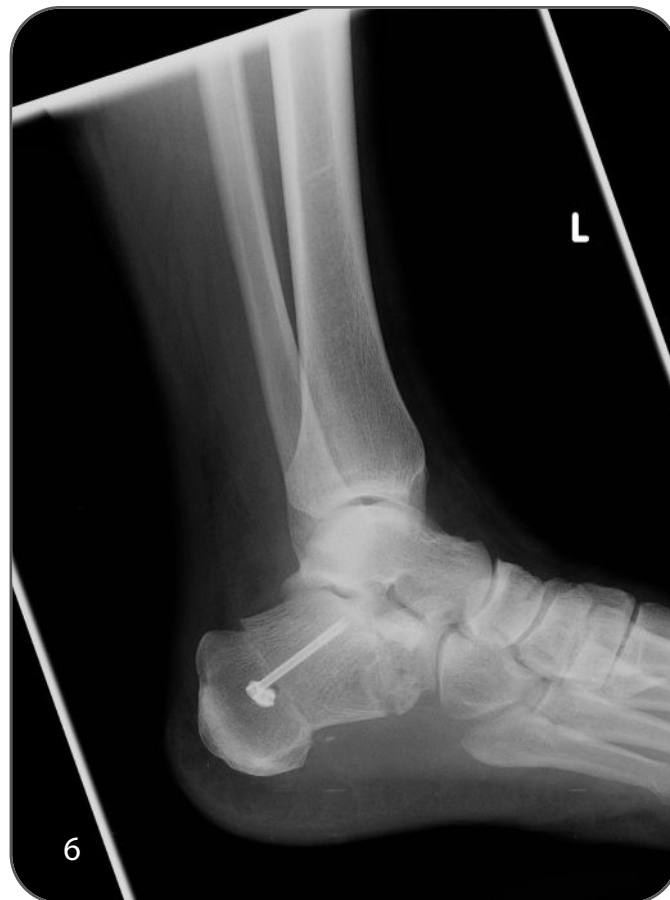Calcaneal axial x-rays were consistent with frontal plane correction of the rearfoot valgus deformity with the solitary X-Post™ interfrag screw fixation in place and a completed consolidated osteotomy with no hardware prominence on either the medial or lateral cortex of the calcaneus.

POSTOPERATIVE COURSE

The patient was followed both radiographically and clinically. The patient did not experience any adverse effects to internal fixation or any wound complications or postoperative infection.

The patient maintained a nonweightbearing status for five weeks, with a passive range of motion initiated three-weeks postoperatively. The patient began protective weightbearing five weeks postoperatively. A formalized physical therapy was begun at seven weeks postoperatively.

Radiographs were taken at one, three, five, and twelve weeks postoperatively. Final radiographs demonstrated complete consolidation across the osteotomy site without fixation prominence or failure. The position of correction was maintained radiographically and clinically.



DISCUSSION

The medial calcaneal slide osteotomy (Koutsogiannis) approach for adult-acquired flatfoot deformity has proven to be very effective in correcting both frontal and sagittal plane deformities associated with flexible pes planovalgus foot condition. The Medial calcaneal slide osteotomy allows the surgeon to correct two planes of deformity by achieving rearfoot realignment while maintaining flexibility and promoting maximum foot function. The IO FiX™ (Intraosseous Fixation) System provides greater uniform compression than standard lag screw fixation. The fixation remains rigid and stable throughout osteotomy healing. The proximal metallic cortex remains constant during all stages of bone healing as the lag screw remains simultaneously engaged in a Morse taper.

There is minimal to zero soft tissue irritation as there is no hardware exposure on either medial or lateral wall of the calcaneus. The IO FiX™ System is very versatile, as there are fixed-angle and polyaxial screws and multiple sizes with both short and long thread options on both the X-Post™ and the interfrag screw.