

Stretch Marks: Treatment Using the 1,064-nm Nd:YAG Laser

ALBERTO GOLDMAN, MD, FLÁVIA ROSSATO, MD, AND CLARISSA PRATI, MD*

BACKGROUND Striae are frequent skin lesions that cause considerable aesthetic concern. The 1,064-nm long-pulsed Nd:YAG laser has been used to promote an increase in dermal collagen and is known to be a laser that has a high affinity for vascular chromophores.

OBJECTIVE This study aims to verify the efficacy of the long-pulsed Nd:YAG laser in the treatment of immature striae.

MATERIALS AND METHODS Twenty patients who had immature striae, i.e., red striae, were treated using the 1,064-nm long-pulsed Nd:YAG laser. The analysis of treatment efficacy was performed by the comparison between the images taken before and after each treatment session as well as through a subjective assessment carried out by the patients themselves.

RESULTS Results were considered satisfactory to both patients and doctors. A higher number of patients (55%) considered the results excellent when compared to the same assessment made by the doctor (40%).

CONCLUSION The clinical improvement of immature striae can be obtained with the use of the 1,064-nm long-pulsed Nd:YAG laser. The low incidence of side effects makes this laser a good alternative in the treatment of these common skin lesions.

The authors have indicated no significant interest with commercial supporters.

Striae or stretch marks are frequent undesirable skin lesions¹ that result in considerable aesthetic concern.² Recent or immature striae are defined as linear bands of smooth skin³ which are erythematous or violaceous and may be itchy and slightly elevated. Such striae maintain their characteristics for a short period, usually approximately 6 to 10 months. In their later stage, they become white, flat, or depressed⁴ and are more difficult to treat. They are commonly found during pregnancy, after a sudden gain or loss of weight, in Cushing's disease, in association with prolonged use of strong systemic or topical corticoids, and due to rapid growth in adolescence⁵ and its consequent skin distention. They are two and a half times more frequent in women¹ and affect up to 90% of pregnant women.⁶ Some authors suggest that the presence of striae on the breasts or thighs, family history, and race are significant predictive factors for the development of striae gravidarum.⁶

The precise etiology and pathogenesis of striae have not yet been clearly explained.^{4,6} The histopathologic findings vary according to the length of time these lesions have been present. Recent striae show a deep and superficial perivascular lymphocytic infiltrate and sometimes eosinophils, as well as dilated venules and edema in the upper part of the dermis. Fully developed, mature lesions present a scant lymphocytic infiltrate around the venules. Collagen bands on the upper third of the reticular dermis are stretched and aligned parallel to the surface of the skin. Elastic fibers seem to be increased in number and grouped in sets as a consequence of the loss of the collagen bands. In later stages, there is a thinning of the epidermis due to a flattening of the rete ridges; there is also a loss of elastic tissue which accompanies the loss of collagen. The elastic fibers seem to be increased—an illusion caused by the thinning of the collagen bands. The loss of both elastic tissue and collagen is requisite for the development of these

*All authors are affiliated with the Department of Plastic Surgery and Dermatology, Clinica Goldman, Porto Alegre, Brazil

conditions. In the end, a reduction in the thickness of the dermis is found.⁵

Among the main therapeutic options are topical tretinoin,⁷ glycolic acid in conjunction with L-ascorbic acid or tretinoin,⁸ the pulsed dye laser, the CO₂ laser, intense pulsed light, and the excimer laser.⁹ It is also known that several lasers have proven efficacy in the induction of new collagen formation.^{10–13} The 1,064-nm long-pulsed Nd:YAG laser has also demonstrated an increase in dermal collagen when used in the nonablative treatment of facial wrinkles.^{14,15} In addition, it is well established in the literature that this laser has a strong attraction to vascular targets,^{16–18} which, associated with its action on dermal collagen, can lead to the beneficial effects observed in the treatment of immature striae. Based on these previous studies, the authors used the 1,064-nm long-pulsed Nd:YAG laser in the treatment of immature striae.

The presence of dilated venules and a superficial perivascular lymphocytic infiltrate in immature striae represent a desirable target for the Nd:YAG laser due to the presence of oxyhemoglobin in the vessels. The 1,064-nm wavelength has good skin penetration and is often used for vascular alterations.^{16–18} Thus, the combination of these qualities enables the photothermal effect of the Nd:YAG laser to effectively treat immature striae.

The capacity for collagen stimulation and the consequent formation of new collagen and the reorganization of the elastic fibers observed after treatment with diverse laser and pulsed light sources^{5,10,12,15} enable a contraction of the striae and an improvement in the quality and texture of the skin in the treated areas.

The histopathologic characteristics present in immature striae are similar to those found in recent scars. This would explain why scars also show a significant improvement after treatment with the 1,064-nm long-pulsed Nd:YAG laser.¹⁹

Materials and Methods

Twenty patients with recent striae had a total of 26 treatment sites; some patients had treatment in more than one area. Ten patients had treatment to the breasts, 5 had treatment to the abdomen, 2 had treatment to the chest, 4 had treatment to the buttocks, 2 had treatment to the flanks, and 3 had treatment to the thighs. No mature white striae were included in this study; the study was conducted from October 2002 to January 2007. The follow-up period was between 3 weeks and 3 years. The patients included in the study had Fitzpatrick Skin Phototypes II to IV and their age varied from 13 to 30 years with a mean age of 18.9 years.

As for the likely etiologic trigger factors for the striae, 12 patients reported that their striae were related to growth, 6 attributed them to recent pregnancy, and 2 attributed their striae to weight increase. Pregnant women were not included in the study and no patient had signs or symptoms suggesting any sort of hormonal alteration. All patients signed informed consent; standard photographic documentation was part of the routine before and after treatment.

Aiming to cool and protect the epidermis as well as to decrease the discomfort during laser treatment, an ice pack or cold air cooling was applied. No patients received any kind of local or topical anesthesia. A thin layer of cold, clear, water-based gel was applied to the treatment areas. After everyone in the room was given adequate eye protection, the lesions were treated with the 1,064-nm long-pulsed Nd:YAG laser (Smartepil, DEKA, Firenze, Italy) with a spot size of 2.5-mm, fluences between 80 and 100 J/cm², a delay of 15 to 20 ms, and a frequency of 2.0 Hz. In each session, each stria was treated over its entire length, avoiding overlapping pulses, as in the technique suggested by Alster and colleagues^{19,20} when using the pulsed dye laser in the treatment of striae or scars. The average number of treatment sessions per patient was 3.45 with an interval of 3 to 6 weeks.

Results

The results obtained with the treatment of immature striae using the 1,064-nm long-pulsed Nd:YAG laser have proven satisfactory according to the assessment of both patients and doctors. Both patients and doctors answered a questionnaire in which the following scale was used: poor, when there was no improvement or improvement up to 30%; good, when the improvement was between 30 and 70%; and excellent, when the improvement was above 70%. These results are shown in Table 1.

Even though there may be improvement in the appearance of recent striae after a single session, the best results were observed after three treatment sessions (Figures 1–4). Among the side effects, there was minimal edema and erythema, which lasted from a few hours to a maximum of 3 days. No further complications such as postoperative purpura, bullae, crusts, ulcerations, or dyschromia were observed and no patient interrupted the treatment due to pain or discomfort.

Discussion

Several treatments have been proposed in an attempt to obtain aesthetic improvement of striae.¹⁹ Although in most cases striae are not related to systemic illness or disease, depending on their extent, location, and the personal perception of the patients, they may cause great aesthetic dissatisfaction and have a profound negative impact on self-esteem.

The advent of laser therapy has represented a breakthrough in the approach to striae. Studies have shown an induced repigmentation of striae

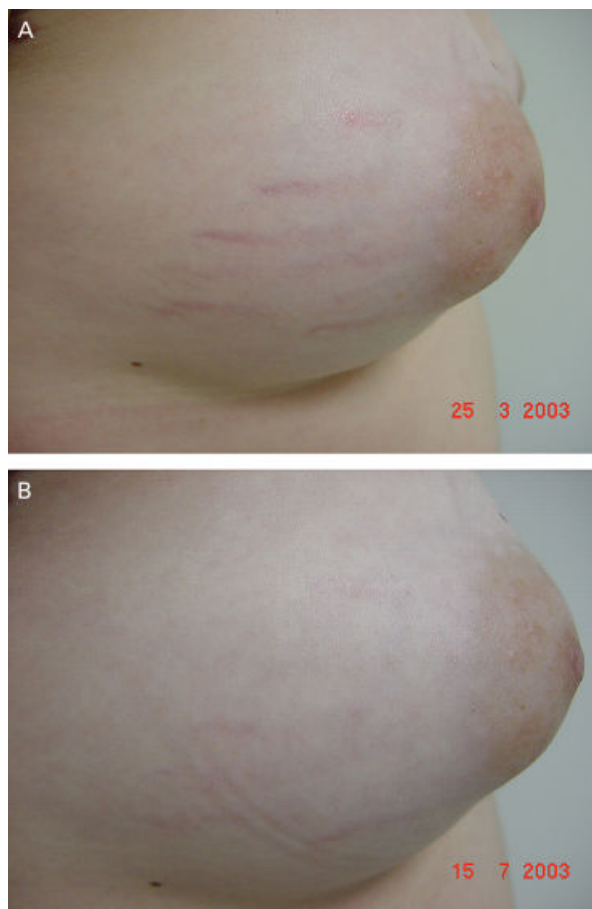


Figure 1. (A) 19-year-old patient with recent striae of the breast. (B) Result after four sessions.

distensae with the use of the ultraviolet B laser and a light source²¹ and that the use of the 308-nm excimer laser is effective in the repigmentation of mature hypopigmented striae.²² The 585-nm pulsed dye laser improves the appearance of mature striae,^{23,24} but Jiménez and coworkers²⁵ only recommend it in striae rubra and in Fitzpatrick Skin Phototype II to IV patients. A study comparing the 585-nm pulsed dye laser and the short-pulsed CO₂ laser suggests that both lasers should be avoided or used with extreme caution²⁶ when treating patients with Skin Phototypes IV to VI. According to Tay and coworkers,⁹ the nonablative 1,450-nm diode laser is also not recommended in the treatment of striae in patients with the same phototypes. Hernandez-Pérez⁵ found a statistically significant difference ($p < .01$) in dermal thickness

TABLE 1. Treatment Evaluation

Results	Patients' Assessment	Doctors' Assessment
Poor	4 patients	4 patients
Good	5 patients	8 patients
Excellent	11 patients	8 patients
Total patients	20 patients	20 patients

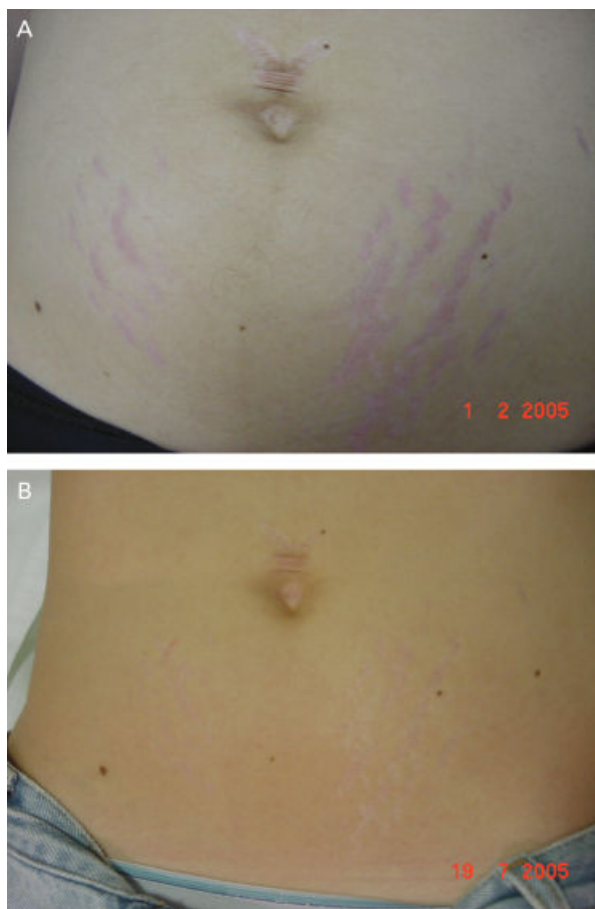


Figure 2. (A) Striae gravidarum of the abdomen. (B) Result after three sessions.

after the treatment of striae distensae using intense pulsed light.

Owing to its physical characteristics, represented mainly by the 1,064-nm wavelength, the laser used in this study is very safe. Complications are rarely produced when the device and parameters are appropriately utilized in either epilation or vascular alterations, even in patients with dark skin. In addition, the cooling of the striae prior to and immediately after the use of the laser represents yet another factor in epidermal protection. Such cooling of the treated areas, however, should not be too long so as to avoid local vasoconstriction and the consequent decrease of the chromophore oxyhemoglobin. The treatment of erythematous striae using the 1,064-nm long-pulsed Nd:YAG laser has demon-

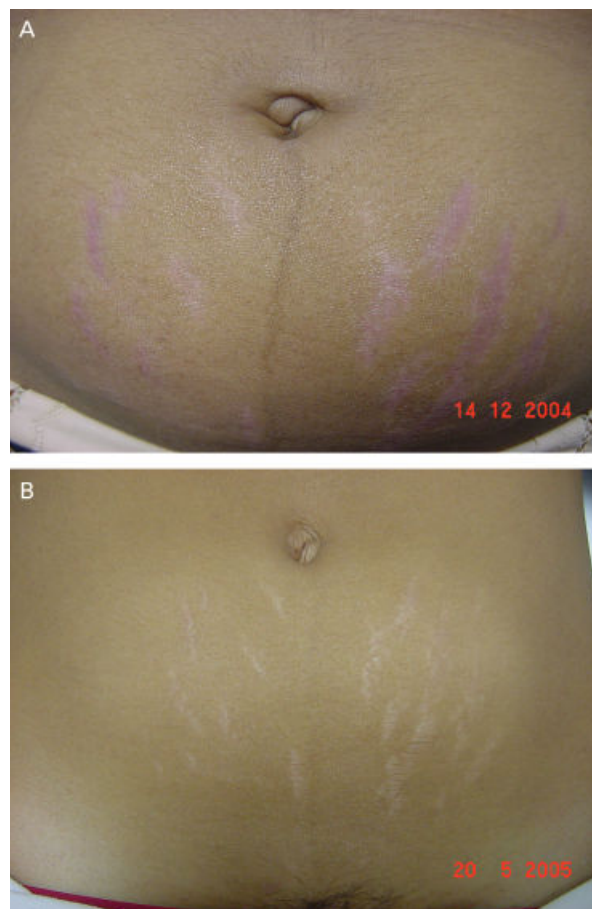


Figure 3. (A) 30-year-old patient with striae gravidarum of the abdomen (Fitzpatrick Skin Phototype IV). (B) Improvement of the appearance after five sessions.

strated a clinical improvement of such lesions, probably due to the laser's affinity for the vascular target present in the striae. The absorption of the laser by its target, i.e., oxyhemoglobin, leads to an improvement in the redness. In addition, it has become evident that, like other luminous sources, the long-pulsed Nd:YAG laser also induces the formation of new collagen; this leads to an improvement in the atrophy of the skin and consequently improves the appearance of immature striae. This improvement was evident for both patients and doctors. The full clearance of the lesions is very rare and seems to be occasionally obtained in some isolated areas of recent striae. Hence, it is vital to start treatment early. According to Sherwin and Goldschmidt,²⁷ once fully formed, striae remain

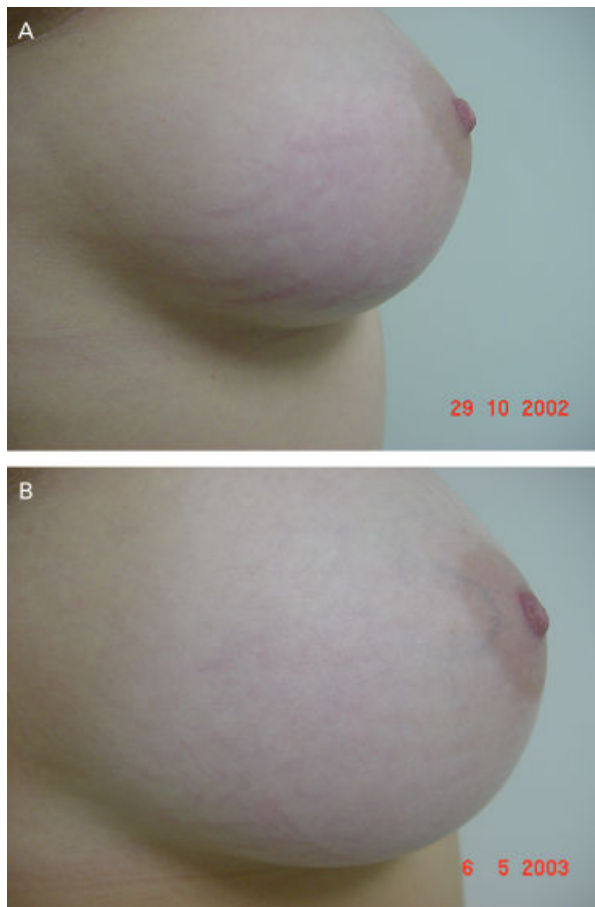

Figure 4. (A) Striae of the breast of a young patient. (B) Result after three sessions.

static, asymptomatic, and unfortunately, completely irreversible; this only reinforces the importance of early treatment. The high incidence of striae in lactating or puerperal women and the low incidence of side effects suggest that, in the opinion and experience of the authors, there is no restriction in the treatment of these two populations. Also, the wavelength chosen allows for the use of this laser in striae on patients with tanned skin and does not hinder the performance of the treatment in summer. The main contraindications for the use of this technique, as in most aesthetic treatments, include patients with unrealistic expectations, pregnancy, and the presence of infectious or inflammatory lesions in the region.^{19,20} In the present study, only immature striae were assessed and one must consider the possibility of using all available techniques, given

that all the treatments hitherto have presented some degree of limitation.

Conclusion

Further studies are necessary for a better understanding of the etiology and pathogenesis of striae to increase the treatment possibilities and efficacy of the equipment available. The results obtained in this study, however, have proven the 1,064-nm long-pulsed Nd:YAG laser safe and effective in the treatment of immature striae. This laser represents yet another tool in the approach to treatment of these common aesthetic deformities.

References

1. Nigam PK. Striae cutis distensae. *Int J Dermatol* 1989;28:426–8.
2. McDaniel DH. Laser therapy of striae. *Dermatol Clin* 2002;20:67–76.
3. Tsuji T, Sawabe M. Elastic fibers in striae distensae. *J Cutan Pathol* 1988;15:215–22.
4. Sheu HM, Yu HS, Chang CH. Mast cell degranulation and elastolysis in the early stage of striae distensae. *J Cutan Pathol* 1991;18:410–6.
5. Hernández-Pérez E, Colombo-Charrier E, Valencia-Ibieta E. Intense pulsed light in the treatment of striae distensae. *Dermatol Surg* 2002;28:1124–30.
6. Chang AL, Agredano YZ, Kimball AB. Risk factors associated with striae gravidarum. *J Am Acad Dermatol* 2004;51:881–5.
7. Elson ML. Treatment of striae distensae with topical tretinoin. *J Dermatol Surg Oncol* 1990;16:267–70.
8. Ash K, Lord J, Zukowski M, et al. Comparison of topical therapy for striae alba (20% glycolic acid/0.05% tretinoin versus 20% glycolic acid/10% L-ascorbic acid). *Dermatol Surg* 1998;24:849–56.
9. Tay YK, Kwok C, Tan E. Non-ablative 1,450 nm diode laser treatment of striae distensae. *Lasers Surg Med* 2006;38:196–9.
10. Michel JL. ED2000®: 585 nm collagen remodelling pulsed dye laser. *J Cosmet Laser Ther* 2003;5:201–3.
11. Fournier N, Dahan S, Barneon G, et al. Nonablative remodeling: clinical, histologic, ultrasound, imaging, and profilometric evaluation of a 1,540 nm Er:Glass laser. *Dermatol Surg* 2001;27:799–806.
12. Prieto VG, Diwan AH, Shea CR, et al. Effects of intense pulsed light and the 1,064 nm Nd:YAG laser on sun-damaged human skin: histologic and immunohistochemical analysis. *Dermatol Surg* 2005;31:522–5.
13. Papadavid E, Katsambas A. Lasers for facial rejuvenation: a review. *Int J Dermatol* 2003;42:480–7.

14. Trelles MA, Álvarez X, Martín-Vásquez MJ, et al. Assessment of the efficacy of nonablative long-pulsed 1,064 nm Nd:YAG laser treatment of wrinkles compared at 2,4, and 6 months. *Facial Plast Surg* 2005;21:145–53.
15. Goldberg DJ, Samady JA. Intense pulsed light and Nd:YAG laser non-ablative treatment of facial rhytids. *Lasers Surg Med* 2001;28:141–4.
16. Sadick NS. Laser treatment with a 1,064 nm laser for lower extremity class I-III veins employing variable spots and pulse width parameters. *Dermatol Surg* 2003;29:916–9.
17. Sadick NS, Prieto VG, Shea CR, et al. Clinical and pathophysiologic correlates of 1,064 nm Nd:YAG laser treatment of reticular veins and venulectasias. *Arch Dermatol* 2001;137:613–7.
18. Major A, Brazzini B, Campolmi P, et al. Nd:YAG 1,064 nm laser in the treatment of facial and leg telangiectasias. *J Eur Acad Dermatol Venerol* 2001;15:559–65.
19. Groover IJ, Alster TS. Laser revision of scars and striae. *Dermatol Ther* 2000;13:50–9.
20. Alster TS, Greenberg HL. Laser treatment of scars and striae. In: Kauvar AN, Hruza G, editors *Principles and Practices in Cutaneous Laser Surgery*. New York: Taylor & Francis; 2005. p. 619–35.
21. Goldberg DJ, Marmur ES, Schmults C, et al. Histologic and ultrastructural analysis of ultraviolet B laser and light source treatment of leukoderma in striae distensae. *Dermatol Surg* 2005;31:385–7.
22. Goldberg DJ, Sarradet D, Hussain M. 308 nm excimer laser treatment of mature hypopigmented striae. *Dermatol Surg* 2003;29:596–9.
23. McDaniel DH, Ash K, Zukowski M. Treatment of stretch marks with the 585 nm flashlamp pumped dye laser. *Dermatol Surg* 1996;22:332–7.
24. Nehal KS, Lichtenstein DA, Kamino H, et al. Treatment of mature striae with the pulsed dye laser. *J Cutan Laser Ther* 1999;1:41–4.
25. Jiménez GP, Flores F, Berman B, et al. Treatment of striae rubra and striae alba with the 585 nm pulsed-dye laser. *Dermatol Surg* 2003;29:362–5.
26. Nouri K, Romagosa R, Chartier T, et al. Comparison of the 585 nm pulse dye laser and the short pulsed CO₂ laser in the treatment of striae distensae in skin types IV and VI. *Dermatol Surg* 1999;25:368–70.
27. Sherwin WK, Goldschmidt H. Lesões atróficas. In: Bondi, Jegasothy, Lazarus, editors *Dermatologia: Diagnóstico e Tratamento*. Porto Alegre, RS: Ed Artes Médicas; 1993. p. 274–83.

Address correspondence and reprint requests to: Alberto Goldman, MD, Av. Augusto Meyer, 163 conj. 1203, Porto Alegre, RS 90550-110, Brazil, or e-mail: alberto@goldman.com.br

COMMENTARY

Stretch marks: treatment for all clinical variants of laser striae remain one of the greatest therapeutic dilemmas in cosmetic dermatology. The quest for improvement has been difficult for early red striae and even more challenging with white mature stretch marks. In this regard anything that is beneficial is thought of as a “holy grail.” Many nonproven topical agents and technologies such as microdermabrasion and carbon dioxide therapy have been mentioned, but not scientifically or clinically substantiated.

From the early pioneering work on red inflammatory striae by Alster and colleagues, employing the pulsed dye laser (PDL; 585–600 nm), which targets hemoglobin, other therapeutic modalities have evolved to deal with more mature white striae. In this regard, two proven approaches have evolved. The first is to remodel the dermis and stimulate collagen and elastic tissue production. This approach has utilized infrared lasers such as the CoolTouch (1,320 nm; CoolTouch, Inc., Roseville, CA and Smoothbeam, Candela, Wayland, MA). Proven studies and results were moderate but positive.

Newer modalities have recently been introduced which show more promise in terms of dermal remodeling and subsequent improvement in terms of white and pigmented striae. The technology receiving most attention in this regard has been fractional photothermolysis sources. Investigators such as Geronemus and colleagues, have shown promising results with three to five treatment sessions employing this therapeutic approach with the Fraxel (1,550 nm; Reliant Technologies, Mountain View, CA). Most laser companies have followed, pursuing similar light source capabilities.

In addition, some progress has been made in improving hypopigmentation in white striae utilizing targeted phototherapy employing UVB/UVA sources have been helpful in this regard. Early technologies have

included the ReLume (Lumenis, Santa Clara, CA) and MultiClear (Curelight, Gladstone, NJ). Transient hyperpigmentation of treated lesions, variable results, and a necessity for long-term maintenance treatments have limited the popularity of this therapeutic approach.

So, we have to think positively about the clinical results noted by the present authors employing the 1,064-nm Nd:YAG laser as it addresses two approaches which have scientific basis for improvement of early striae. The chromophore targeting of hemoglobin improves erythema and long-term dermal remodeling improves surface contour irregularities.

Three important points should be taken away by the reader. First, it is easier to improve early inflammatory striae than late-stage hypopigmented clinical lesions. Second, we are still a long way away from having a reproducible, truly effective treatment modality to address striae. Finally, more research and clinical trials should be encouraged to continue to look for more effective long-lasting clinical approaches for a cosmetic problem, which is a concern for a large segment of the world wide female population.

NEIL SADICK, MD
New York, NY