



A new 675-nm laser device in the treatment of acne scars: an observational study

Giovanni Cannarozzo¹ · Martina Silvestri² · Federica Tamburi² · Claudia Sicilia² · Ester Del Duca³ · Elisabetta Scali² · Luigi Bennardo² · Steven Paul Nisticò²

Received: 17 February 2020 / Accepted: 4 June 2020
© Springer-Verlag London Ltd., part of Springer Nature 2020

Abstract

Purpose Acne scarring represents a common problem that negatively impacts patients' quality of life. Different types of treatments are currently available for this dermatological condition. This study evaluates the efficacy of a new 675-nm laser source system on acne scars with the use of established parameters that guarantee minimum pain and the absence of side effects such as hyperpigmentation, hypopigmentation, and blistering.

Methods A total of 24 subjects (all women, aged 21–42 years), with Fitzpatrick skin types I–IV and facial acne scars, were treated with three sessions of a 675-nm laser system. Efficacy of treatment was evaluated using the Goodman and Baron's quantitative grading scale before and 3 months after the last treatment.

Results All 24 patients treated with this new 675-nm laser had significant improvement of acne scars according to Goodman and Baron's Quantitative Global Acne Scarring Grading System. No side effect has been observed except some minor erythematous reactions in three patients.

Conclusion The 675-nm laser system we used appears to be effective and well-tolerated in patients with acne scars, and it involves a simple post-treatment management.

Keywords Acne scars · Acne scars treatment · 675-nm laser · Laser

Introduction

Inflammatory acne can cause different types of scars. These scars negatively affect patient's relational and social life. The abnormal production or degradation of collagen that occurs in healing processes leads to various types of acne scars. In most cases (80–90%), there is a degradation of collagen at the dermal level which results in atrophic scarring. More rarely, there is an increased production of collagen which causes hypertrophic or keloid scars [1]. Atrophic acne scars can be subclassified into three different types: ice pick type (60–70%),

boxcar (20–30%), and rolling scars (15–25%) [2]. Different treatments are available: chemical peels, dermal brasion/micro-dermal brasion, laser treatments, punch techniques, and combined therapies for atrophic scars: silicone gel, intralesional steroid therapy, cryotherapy, and surgery for hypertrophic scars and keloids [3]. Various methods have been proposed in order to classify acne severity [4]. Goodman and Baron's Quantitative Global Acne Scarring Grading System (GBGS) is clinically useful and is a simple method for assessing the severity of acne scars, ranging from 0 to 84 points. It is based on scar counting (1–10, 11–20, > 20), scar morphology (atrophic, macular, boxcar, hypertrophic, keloidal), and severity (mild, moderate, severe) [5].

Treatment of acne scars involves the use of different types of lasers, ablative and non-ablative. Ablative lasers, targeting water, allow the removal of damaged scar tissue by vaporization (carbon dioxide laser, Erbium YAG laser) [6]. Non-ablative lasers stimulate dermal fibroblasts to produce new collagen (NdYAG and Diode lasers). The 675-nm RedTouch laser (Deka Me.La, Italy), used in this study, is a non-ablative laser system that induces remodeling of atrophic

✉ Luigi Bennardo
luigibennardo10@gmail.com

¹ Department of Dermatology, University of Rome "Tor Vergata", Rome, Italy

² Unit of Dermatology, Department of Health Science, Magna Graecia University, Catanzaro, Italy

³ Department of Dermatology, Mount Sinai Medical Center, New York, NY 10029, USA

scars, reducing the risk of side effects and simplifying post-treatment management.

The system emits a 675-nm wavelength red light through a 15 × 15-mm scanning system capable of generating micro-zones of sub-ablative and selective thermal damage on the skin as reported in preclinical studies.

In addition to power and pulse duration, the distance between microthermal zone of damage has been added as a third operating parameter.

The depth reached at each emission may reach 300 µm. Therefore, a thermal column is formed; this thermal column diffuses heat to the surrounding areas causing immediate shrinkage and denaturation of the collagen with subsequent new collagen formation.

There has been evidence that the different possible combinations of the above mentioned operating parameters allow different effects in order to treat various aspects of skin aging. The versatility of the system induced us to investigate treatment of post-acne scars.

The system is also equipped with a 5 °C skin cooling system in order to preserve epidermis from damage caused by the increase in temperature. The device is promising in the remodeling of atrophic scars, as the laser hits selectively collagen fibers without interacting with the vascular component of the dermis; therefore, risks of side effects and post-treatment management are minimized.

Materials and methods

The study included 24 patients (all women, 21–42 aged years) with Fitzpatrick skin types I–IV and residual acne scars evaluated by GBGS, assessed by an investigator. These patients were treated at the Dermatology Department of University of Rome “Tor Vergata” and the Dermatological Unit of Magna Graecia University in Catanzaro, Italy. This study was approved by ethical committee Calabria Centro with the reference number 373/2019. Patients were treated with 3 sessions of the RedTouch laser (power, 10 W; dwell time, 300–400 ms;

spacing, 1–1.5 mm; cooling, 5 °C) with a 1-month interval between sessions. Device technical specifications are reported in Table 1. Only three patients were treated with topical anesthetic ointment. All treatments have been performed with the use of a transparent conductive gel.

Exclusion criteria for the study were the following: (1) patients hypersensitive to light in the red and near-infrared wavelength region, (2) the use of medications that is known to increase sensitivity to sunlight, (3) the use of anticoagulants and/or immunosuppressants, (4) patients with seizure disorders triggered by light, (5) pregnant patients, (6) patients with personal or family history of skin cancer, (7) patients who have been directly exposed to the sun for several hours during the 3 weeks prior to treatment (for any skin type), and (8) the presence of tattoos or skin disorders on the areas to be treated.

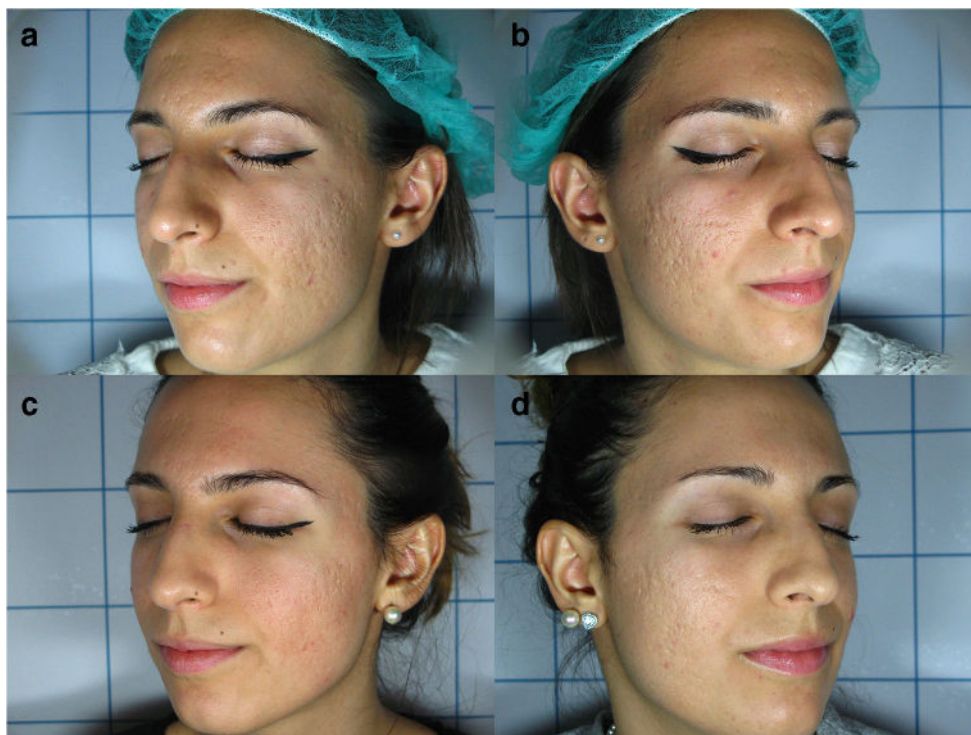Before starting the treatment, areas to be treated were cleaned with a mild soap rinsed with water. Assessment of the energy to treat each patient was carried out on a “test” area based on the subject’s skin type and degree of tolerability. The answer of the test was noticeable within 5/10 min. The end point was considered a mild erythema and some associated edema.

Treatment was carried out by passing the handpiece in contact with the skin surface, without excessive pressure, with spots that follow one another without overlapping, but without leaving untreated areas. The same area underwent two laser passes in order to avoid minor burns and/or hyperpigmentation. Areas close to the bone surface (forehead, cheekbone, etc.) were treated with only one passage, in order to avoid burns as they have a thinner dermis. Application of topical anesthetics was optional: the patient started the procedure without topical anesthetics. If pain was severe, procedure was stopped, and a 7% lidocaine/7% tetracaine anesthetic cream was applied. Treatment was then resumed after 40 min. This cream was used in only three of the patients and completely removed before treatment. After treatment, skin was cooled with gauzes soaked in cold water, and a non-steroidal anti-inflammatory cream based on beta glucan and sodium hyaluronate was applied twice a day for 2 weeks.

Table 1 Device technical specification available/used in the protocol

Technical specifications	Available	Used in the protocol
Wavelength	675 nm	675 nm
Power	Up to 10 W	10 W
Scan area size	Up to 15 mm × 15 mm	15 mm × 15 mm
Scanning shapes	Point, line, triangle, ellipse, hexagon, square	Square and ellipse
scan modes	Normal, interlaced, SmartTrack	SmartTrack
Dwell time	50–1000 ms	300–400 ms
Spacing	0–4 mm	1–1.5 mm
SmartStack	1–5	1
Integrated skin cooler	Down to 5 °C	5 °C

Fig. 1 **a** Patient at baseline left side. **b** Patient at baseline right side. **c** 3-month follow-up left side. **d** 3-month follow-up right side



Post-operative recommendations included the use of total block mineral sunscreens. Efficacy of the treatment was assessed using three methods: (1) comparison of digital photographs before and 3 months after the last treatment, (2) Goodman and Baron's quantitative grading scale assessed by an investigator as compared with the baseline, (3) Visual Analogue Scale (VAS) of 10 points (0, none; 1–2, slight pain; 3–6, moderate pain; 7–8, severe pain, 9–10, intolerable pain) to evaluate tolerance.

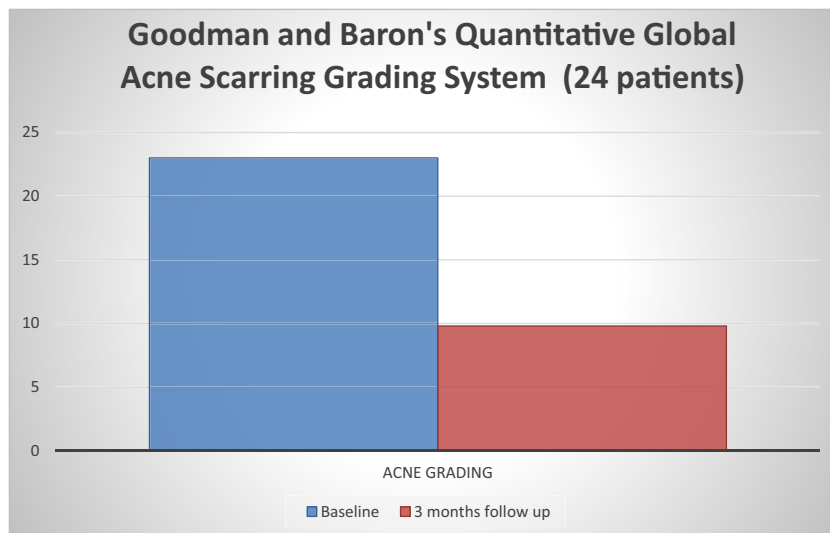
The appearance of side effects such as blistering, scarring, burns, hypopigmentation, or hyperpigmentation has also been

monitored. Statistical analysis was executed using paired Student's *T* test.

Results

All 24 patients treated with RedTouch had significant improvement of acne scars according to Goodman and Baron's Quantitative Global Acne Scarring Grading System and photographic evaluation. The scores decreased significantly from baseline to 3 months follow-up after the last treatment

Fig. 2 Goodman and Baron's Quantitative Global Acne Scarring Grading System



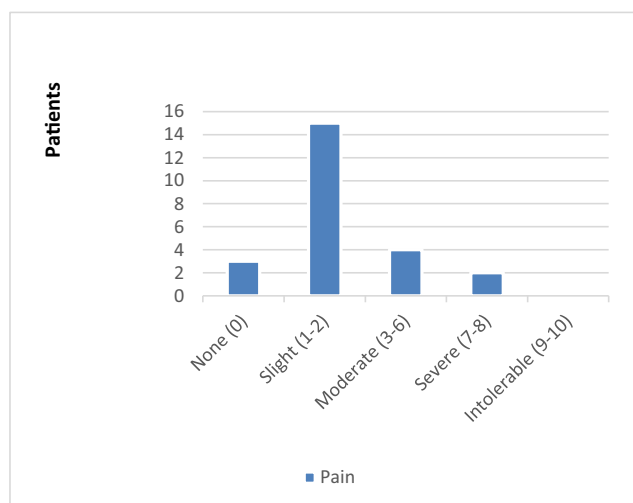


Fig. 3 Pain VAS during treatment

(scores— 23 ± 7003 to 9.85 ± 4.26 , $p = 0.001$) (Fig. 1). Treatment was well-tolerated (pain score, 2.9 ± 2.3) by all patients. The only side effect, occurred in three patients, consisted of small burns due to incorrect positioning of the handpiece on the skin which was resolved in 10 days (Figs. 2 and 3). Patient characteristics are reported in Table 2.

Discussion

Scarring is one of the most common complications of acne vulgaris that appears most frequently on the face and can be associated with low self-esteem, depression, anguish, anxiety, unemployment, and even suicide. The pathogenetic mechanism underlying the formation of these scars lies in the rearrangement of the collagen that occurs following the healing processes of inflammatory lesions. In fact, in the early stages of atrophic scar development, abnormalities in the metabolism of collagen and elastic fibers have been observed [7]. Considering the variations in collagen that occur in post-acne healing processes, the 675-nm wavelength emitted by the RedTouch device that has high affinity for collagen fiber represents a promising treatment strategy for the remodeling of scars. Compared with the systems currently in use for the treatment of acne scarring (NIR 1320–1540 nm) that target water, the RedTouch system acts directly on the collagen component contained in the skin. Light in the spectral range of the “optical window” (~650–950 nm) can reach deep structures of biological tissues, as NIR light is only weakly absorbed by water, hemoglobin, collagen, and proteins. Light below 650 nm is too heavily absorbed mainly by

Table 2 Patient characteristics

ID	Sex	Age	Photo type	Acne scarring grading system before treatment	Acne scarring grading system after 3 months visit	Pain VAS	Side effect
1	F	22	2	12	9	6	None
2	F	37	2	20	10	2	None
3	F	42	2	20	8	2	None
4	F	21	2	26	13	2	None
5	F	29	3	34	3	2	None
6	F	28	1	27	9	6	Burns
7	F	34	2	18	6	0	None
8	F	31	3	22	12	2	None
9	F	25	2	32	15	2	None
10	F	21	3	24	11	2	None
11	F	32	2	29	13	2	None
12	F	39	2	15	4	0	None
13	F	25	2	21	7	2	None
14	F	22	3	19	7	6	Burns
15	F	42	2	20	8	2	None
16	F	28	3	13	6	8	None
17	F	25	2	32	16	0	None
18	F	32	1	32	17	2	Burns
19	F	29	3	31	12	8	None
20	F	28	3	10	3	2	None
21	F	21	2	28	16	6	None
22	F	24	4	16	6	2	None
23	F	28	3	29	16	2	None
24	F	27	2	22	10	2	None

hemoglobin and over 950 nm too strongly from the water. In the spectral range of the “optical window,” various substances, including collagen, have a higher absorption coefficient than water [8].

The treatment is easy to perform and non-invasive, and involves minimal side effects (redness, rare micro-burns). The procedure is also not very painful thanks to the preventive skin cooling. Red Touch creates micro-zones of thermal damage of about 1 mm which, supported by the cooling and the selectivity of the dermal layer, do not damage the epidermal layer. There is neither formation of microscopic epidermal necrotic debris (MENDs) nor dermo-epidermal detachment typical of the post-operative course of NIR systems and probably related to the greater focus on small spots (100–300 µm). The absence of crusts and/or microcrusts during the post-operative course determines a minimal impact on the relational life of the patients. The RedTouch’s ability to act on both melanin and collagen fibers makes this device promising for the treatment of the chrono-aging, photoaging, and pigmented disorders.

In conclusion, the results of this study show that the 675-nm laser source system is an effective method for treating acne scars; furthermore, it is associated to a low risk of side effects and simplifies post-treatment management.

Compliance with ethical standards

Conflict of interest The authors declare that they have no conflict of interest.

Ethical approval All procedures performed in studies involving human participants were in accordance with the ethical standards of the institutional and/or national research committee (Committee “Calabria Centro”

with reference number 373/2019) and with the 1964 Helsinki Declaration and its later amendments or comparable ethical standards.

Informed consent Informed consent was obtained from all individual participants included in the study.

References

1. Connolly D, Vu HL, Mariwalla K, Saedi N (2017) Acne scarring-pathogenesis, evaluation, and treatment options. *J Clin Aesthet Dermatol* 10(9):12–23
2. Fabbrocini G, Annunziata MC, D’Arco V et al (2010) Acne scars: pathogenesis, classification and treatment. *Dermatol Res Pract* 2010: 893080
3. Mercuri S, Brianti P, Cestone E, Dattola A, Nisticò SP (2018) Effective use of nonablative fractional laser on multiple whip scars. *Photomed Laser Surg* 36(6):337–339
4. Melina A, Dinh N, Tafuri B, Schipani G, Nisticò S, Cosentino C, Amato F, Thiboutot D, Cherubini A (2018) Artificial intelligence for the objective evaluation of acne investigator global assessment. *J Drugs Dermatol* 17(9):1006–1009
5. Goodman GJ, Baron JA (2006) Postacne scarring—a quantitative global scarring grading system. *J Cosmet Dermatol* 5(1):48–52
6. Mercuri SR, Brianti P, Dattola A, Bennardo L, Silvestri M, Schipani G, Nisticò SP (2018 Jul) CO2 laser and photodynamic therapy: study of efficacy in periocular BCC. *Dermatol Ther* 31(4):e12616
7. Moon J, Yoon JY, Yang JH, Kwon HH, Min S, Suh DH (2019) Atrophic acne scar: a process from altered metabolism of elastic fibres and collagen fibres based on transforming growth factor-β1 signalling. *Br J Dermatol* 181(6):1226–1237
8. Scholkmann F, Kleiser S, Metz AJ, Zimmermann R, Mata Pavia J, Wolf U, Wolf M (2014) A review on continuous wave functional near-infrared spectroscopy and imaging instrumentation and methodology. *Neuroimage*. 85(Pt 1):6–27

Publisher’s note Springer Nature remains neutral with regard to jurisdictional claims in published maps and institutional affiliations.