



The Newest Platform for Hair Removal Specialists

DEKA Intelligent Technologies:
Experts from the Start

www.dekalaser.com



MEDICINE AND AESTHETICS

SYNCHRO REPLA:Y



The Code of Excellence

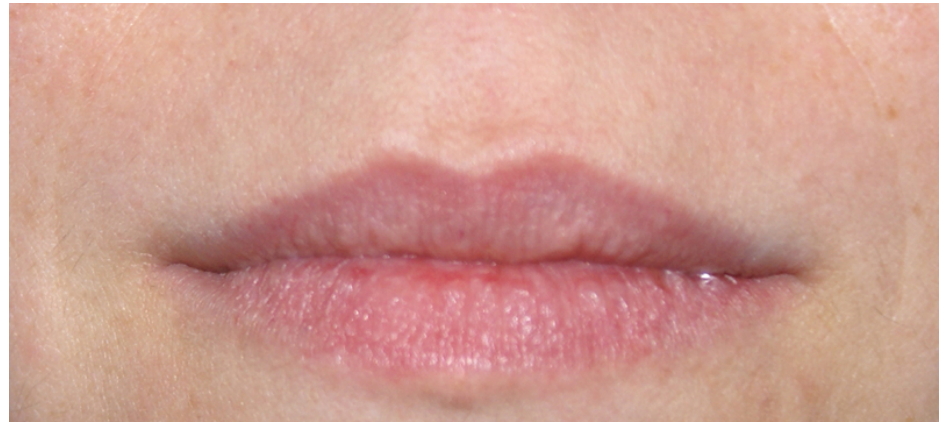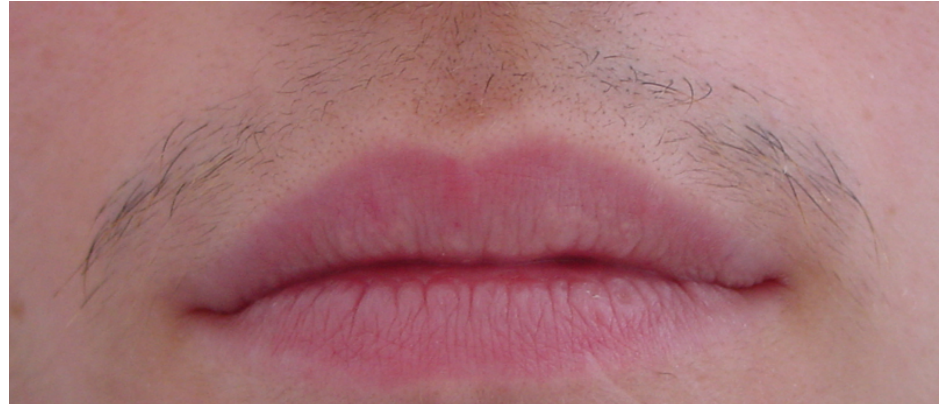Clinical Cases

Hair Removal – Alexandrite

Hirsutism with Hormonal Anomalies

Caucasian female

Phototype III



Courtesy of N. Zerbinati, MD
Department of Clinical and Dermatological Science.
University of Insubria. Varese, Italy.

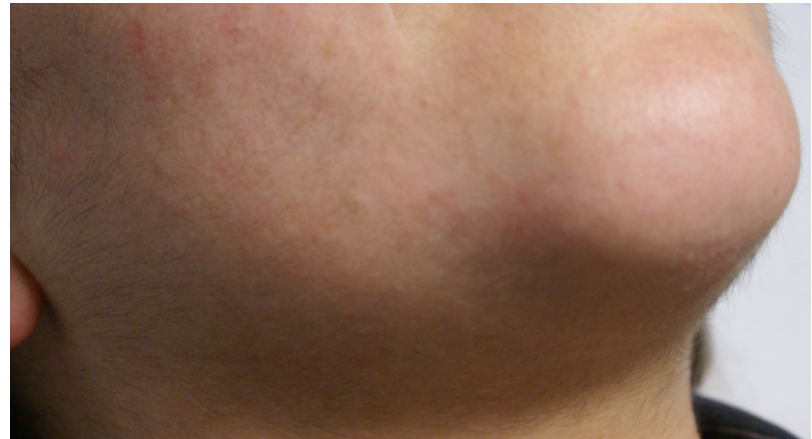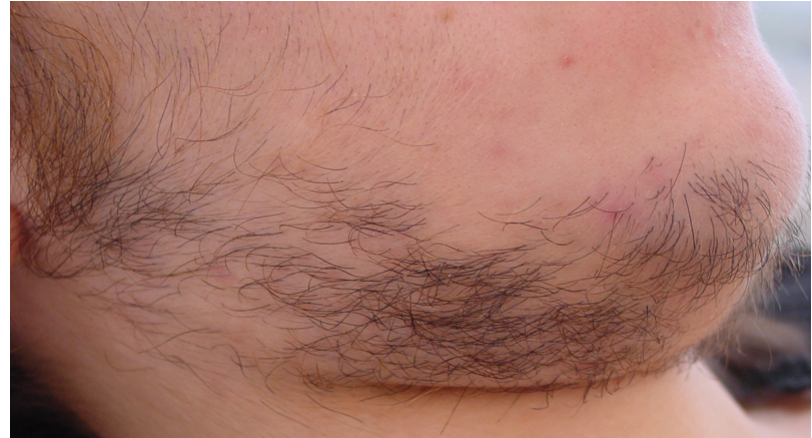MEDICINE AND AESTHETICS

Hair Removal – Alexandrite

Hirsutism with Hormonal Anomalies

Caucasian female

Phototype III



Courtesy of N. Zerbinati, MD
Department of Clinical and Dermatological Science.
University of Insubria. Varese, Italy.

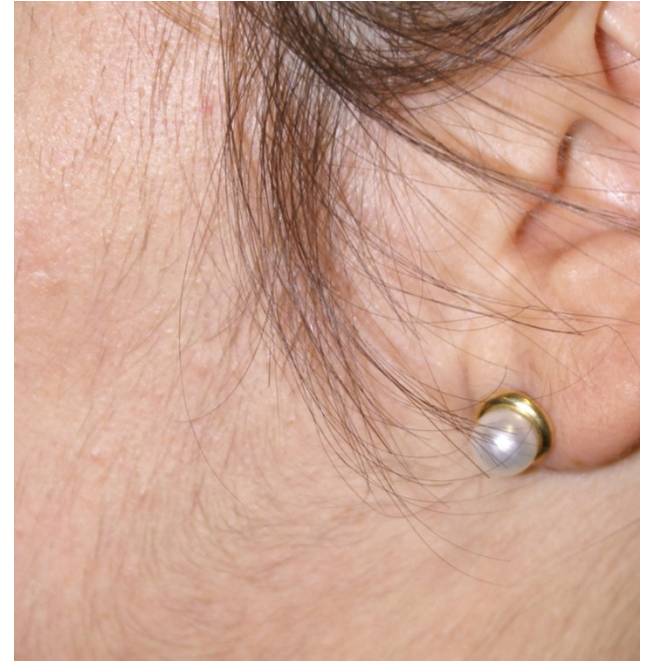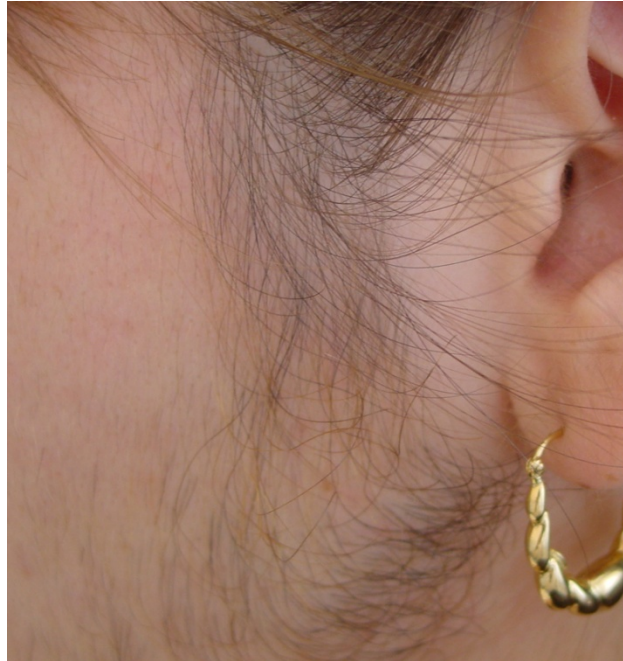MEDICINE AND AESTHETICS

Hair Removal – Alexandrite

Hirsutism with Hormonal Anomalies

Caucasian female

Phototype III



Courtesy of N. Zerbinati, MD
Department of Clinical and Dermatological Science.
University of Insubria. Varese, Italy.

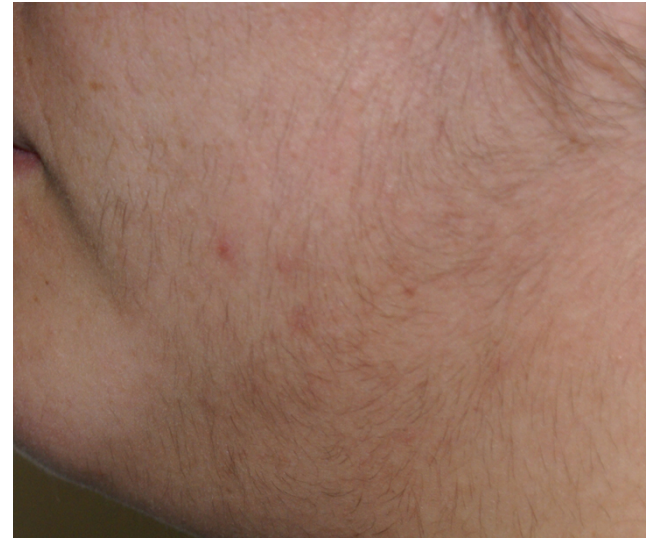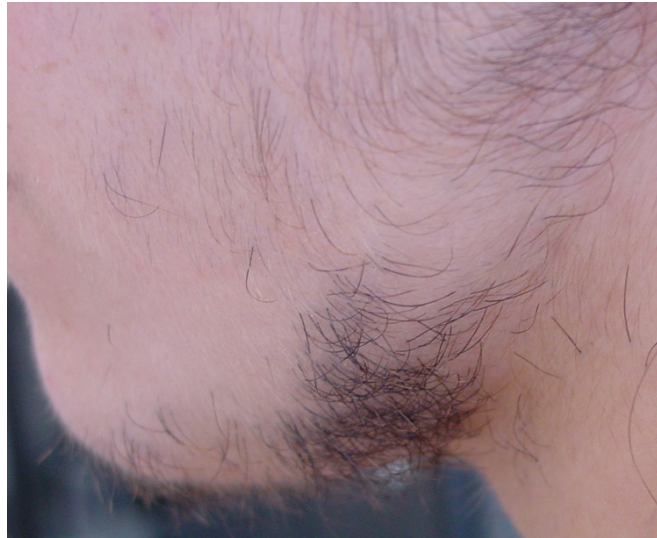MEDICINE AND AESTHETICS

Hair Removal – Alexandrite

Hirsutism with Hormonal Anomalies

Caucasian female

Phototype III



Courtesy of N. Zerbinati, MD
Department of Clinical and Dermatological Science.
University of Insubria. Varese, Italy.

MEDICINE AND AESTHETICS

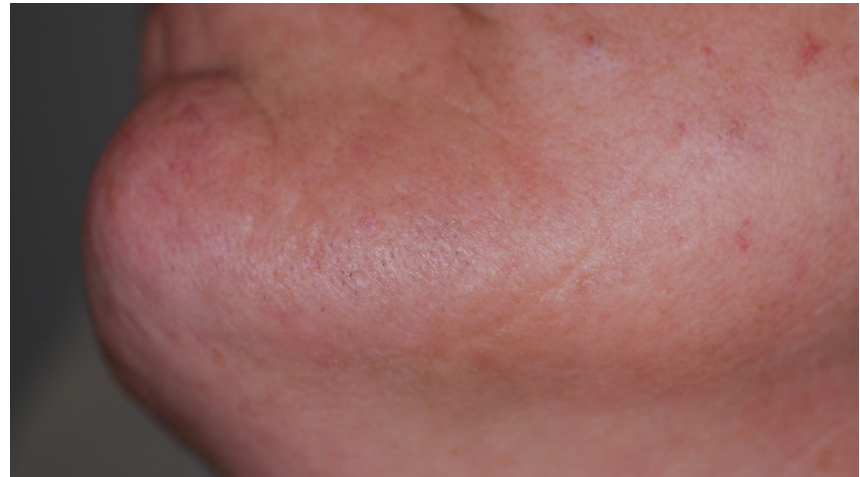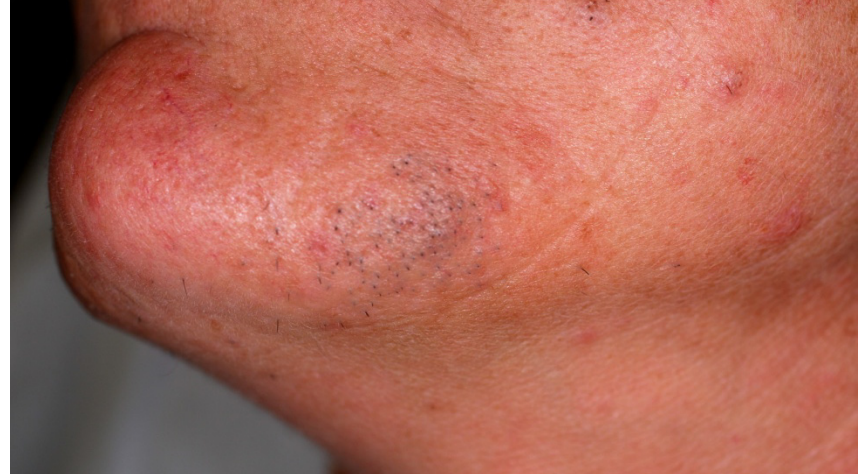Hair Removal – Alexandrite

Hirsutism with Hormonal Anomalies

Caucasian female

Phototype III

Nr. of treatments: 3



Courtesy of M. Patarin, MD - Challans, France.

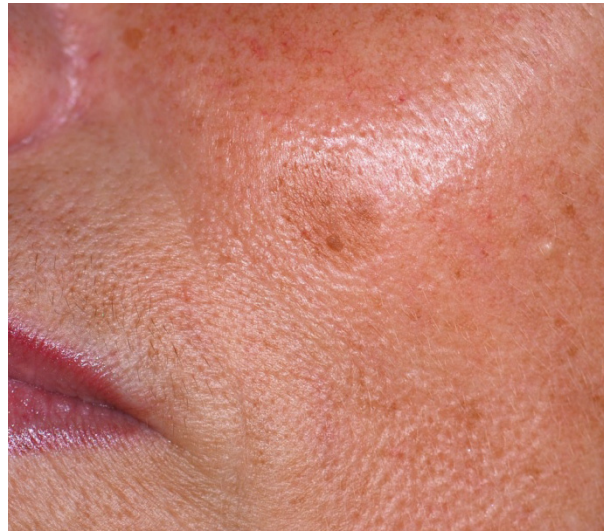MEDICINE AND AESTHETICS

Benign Pigmented Lesion – Alexandrite

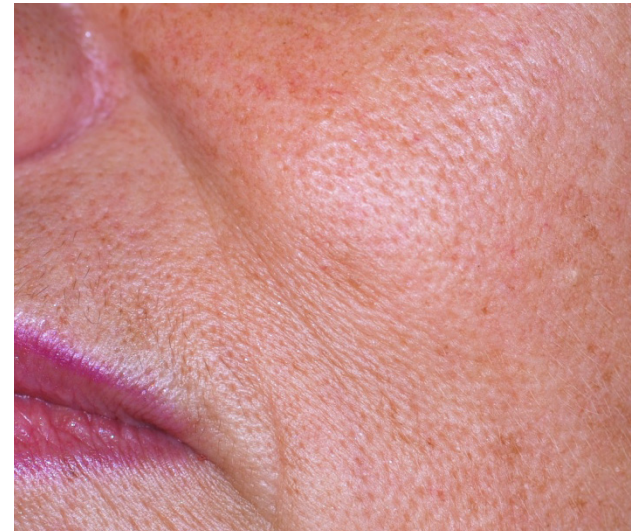Lentigo

Caucasian female

Nr. of treatments: 1



Before the treatment



1 month after 1 session

Courtesy of M. Patarin, MD - Challans, France.

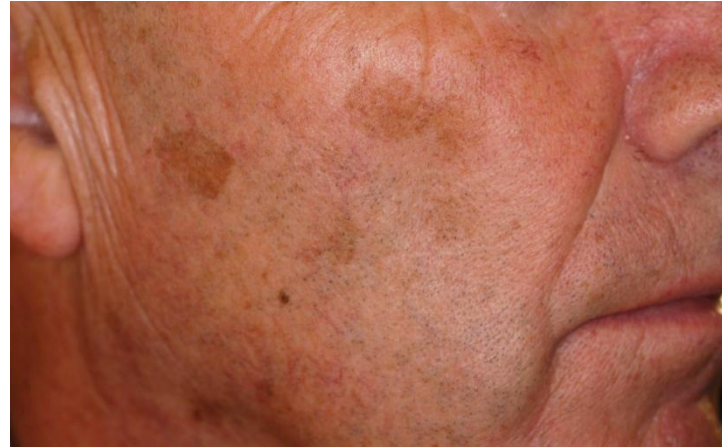MEDICINE AND AESTHETICS

Benign Pigmented Lesion – Alexandrite

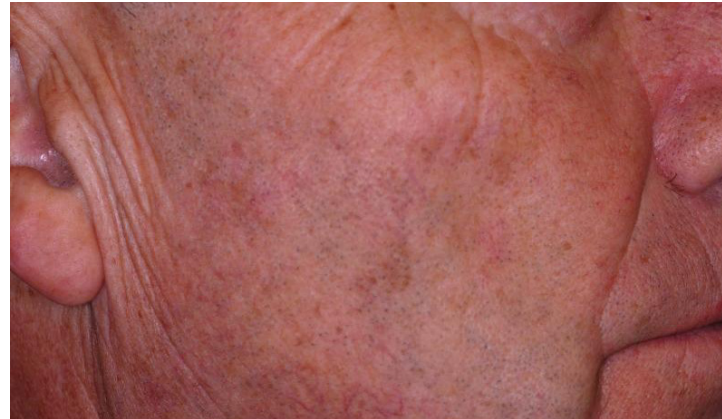
Lentigo

Caucasian male

Nr. of treatments: 1



Before the treatment



1 month after 1 session

Courtesy of M. Patarin, MD - Challans, France.

MEDICINE AND AESTHETICS

Hair Removal – Nd:YAG

Hirsutism with Hormonal Anomalies

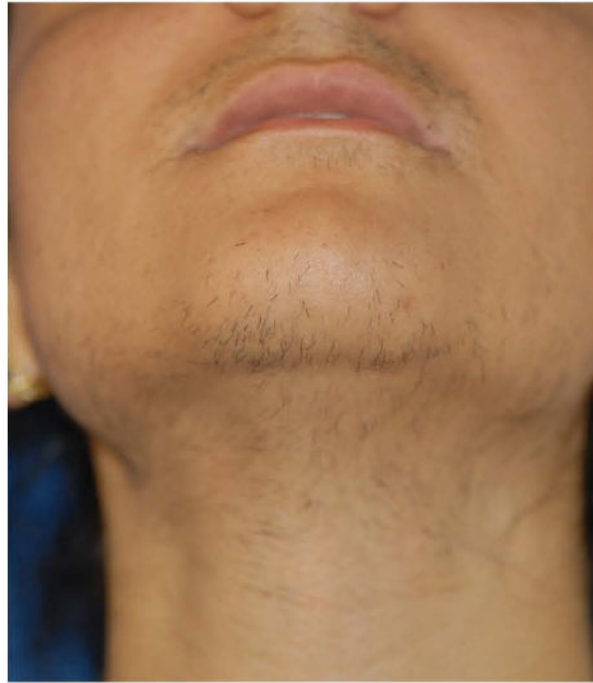27-years old
Caucasian female

Phototype V

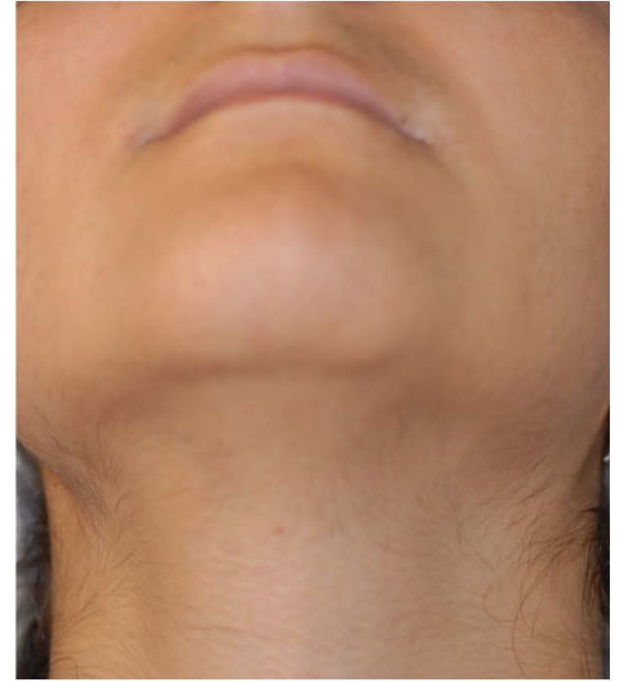
Nr. of treatments: 5

No possibility to use
contraceptive therapy for
reducing hairs number.

High risk of paradoxical
stimulatory effect due to non-
treated hyperandrogenia.



Before the treatment



Two months after the 5th treatment

Courtesy of A. Le Pillouer – Prost, MD
Specialist in Dermatology and Venereology. Marseille, France.

MEDICINE AND AESTHETICS

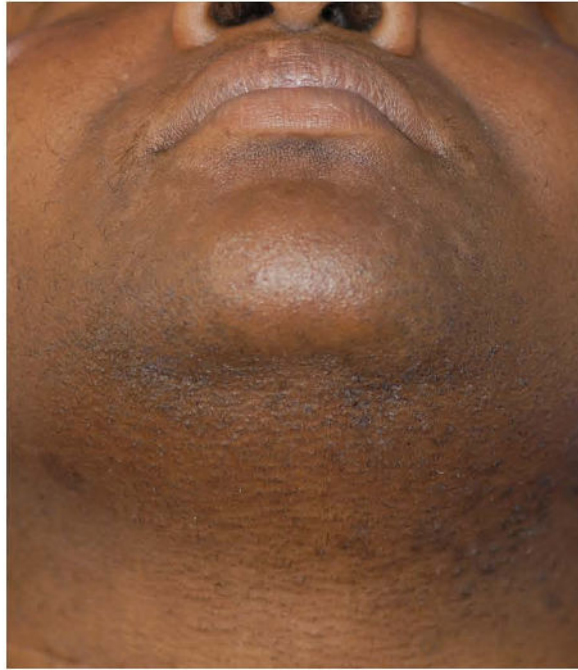Hair Removal – Nd:YAG

Hirsutism with Hormonal Anomalies

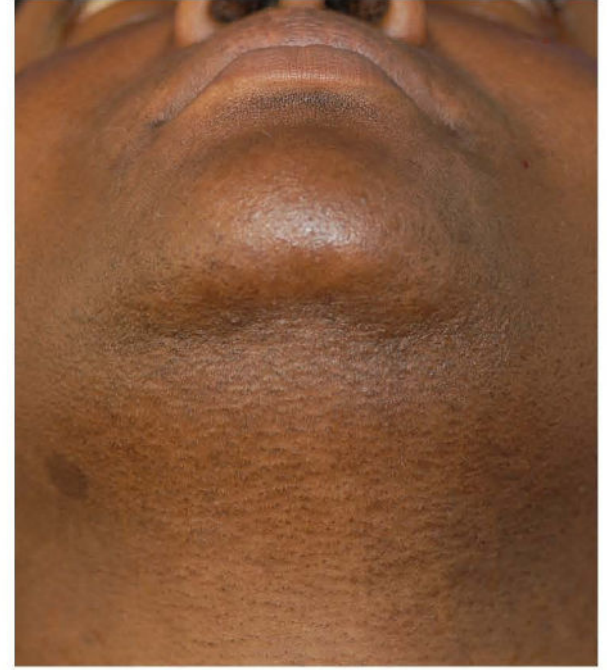
42-years old
African female

Phototype VI

Nr. of treatments: 6



Before the treatment



Two months after the 6th treatment

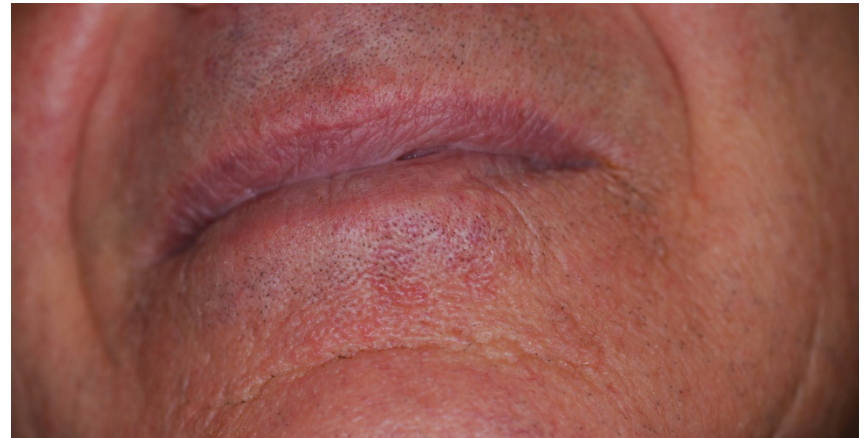
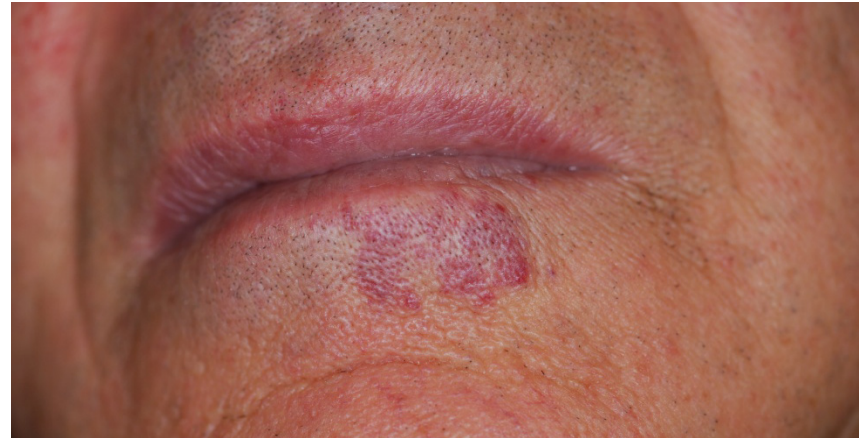Courtesy of A. Le Pillouer – Prost, MD
Specialist in Dermatology and Venereology. Marseille, France.

MEDICINE AND AESTHETICS

Vascular Lesions – Nd:YAG

**Congenital
Angioma
Resistant to KTP
Laser Treatment**

Nr of treatments: 2



Courtesy of M. Patarin, MD - Challans, France.

MEDICINE AND AESTHETICS

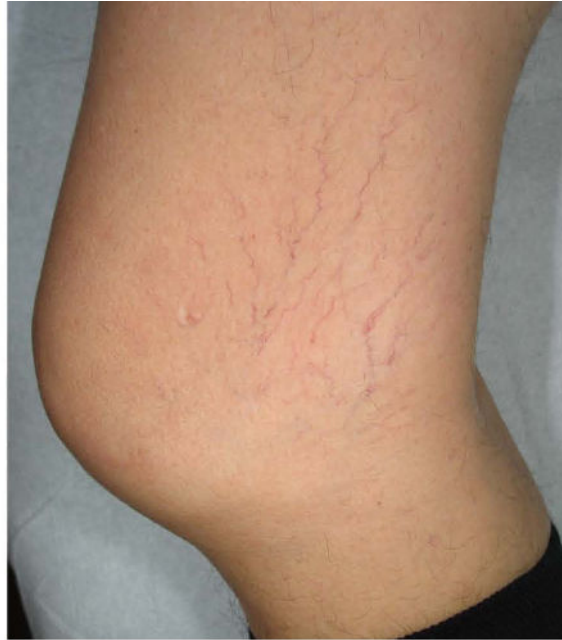Vascular Lesions – Nd:YAG

Lower Limbs Teleangiectasias

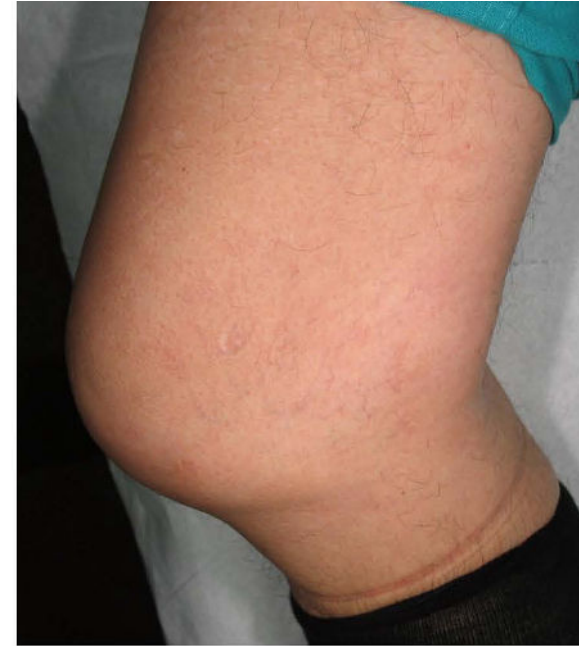54-years old
Caucasian male

Phototype III

Nr of treatments: 1



*Before the treatment
(picture taken using polarized light)*



*Three months after a single treatment
(picture taken using polarized light)*

Courtesy of

P. Bonan, MD – P. Campolmi, MD – G. Cannarozzo, MD

Department of Dermatology. University of Florence, Italy

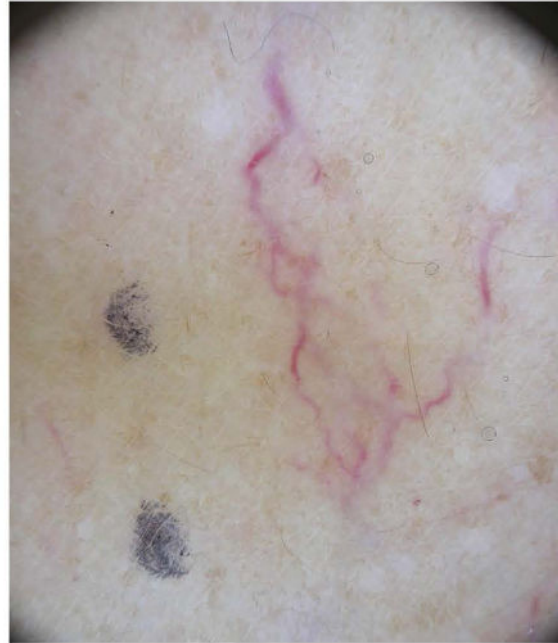Vascular Lesions – Nd:YAG

Lower Limbs Teleangiectasias

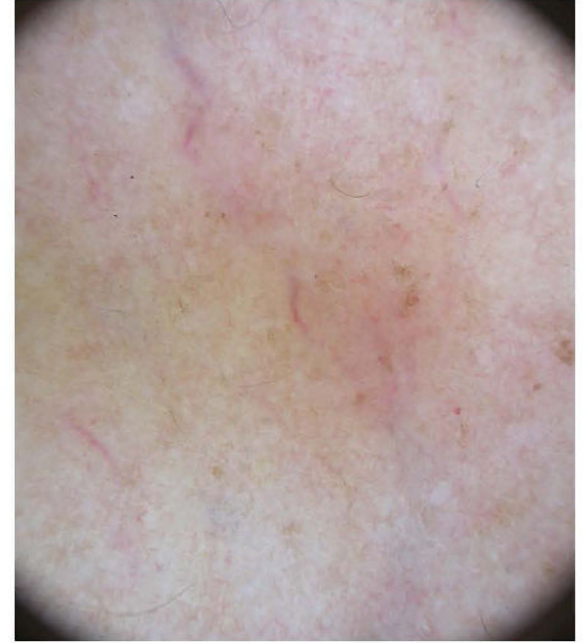46-years old
Caucasian female

Phototype II

Nr. of treatments: 3



Before the treatment (macro)



Immediately after the 1st treatment (macro)

Courtesy of

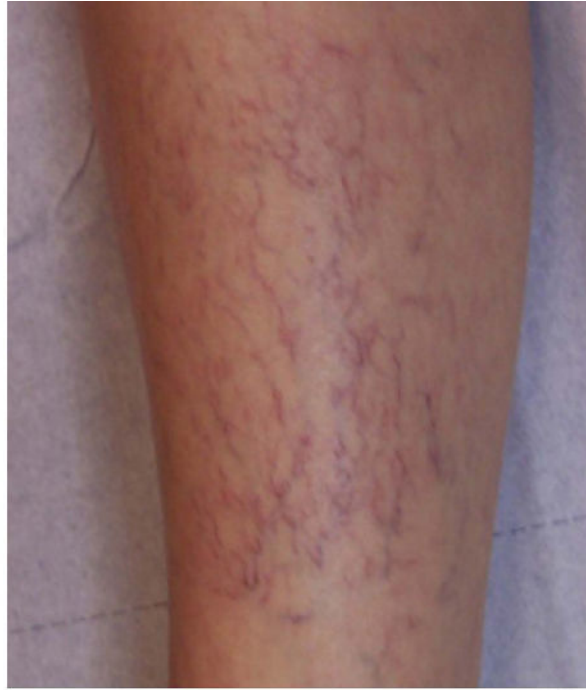
P. Bonan, MD – P. Campolmi, MD – G. Cannarozzo, MD

Department of Dermatology. University of Florence, Italy

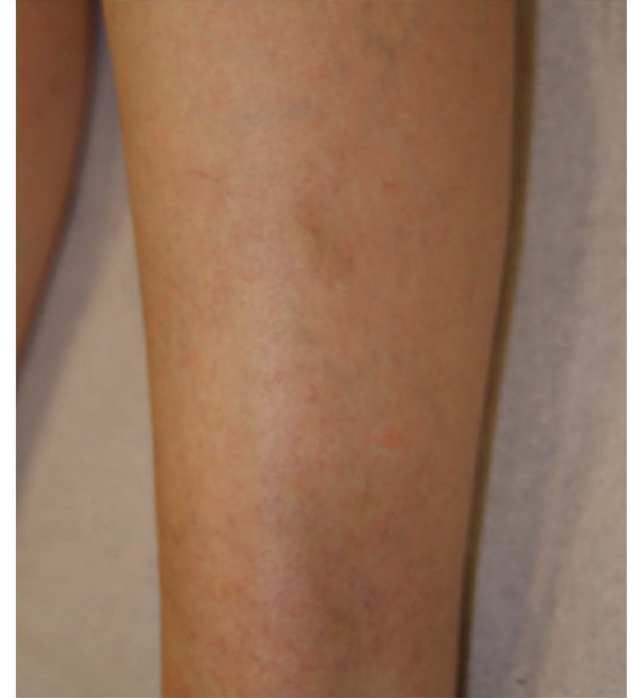
Vascular Lesions – Nd:YAG

Lower Limbs Teleangiectasias

Nr. of treatments: 2



Before the treatment



Two months after the 2nd treatment

Courtesy of L. Mazzi, MD
Specialist in Dermatology and Venereology. Verona Italy.

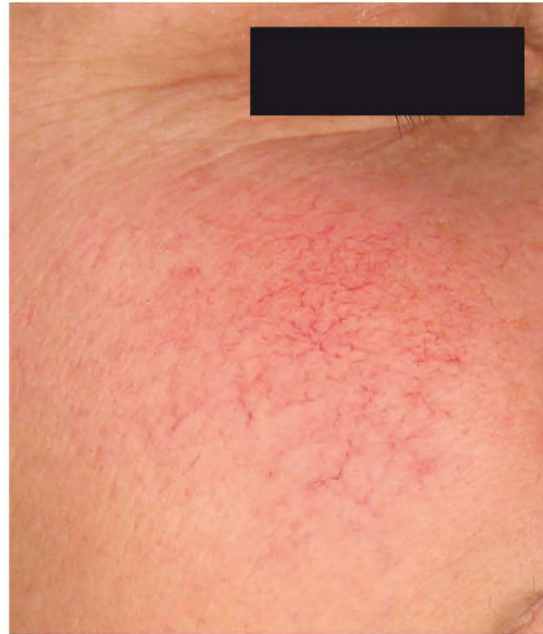Vascular Lesions – Nd:YAG

Face Teleangiectasias

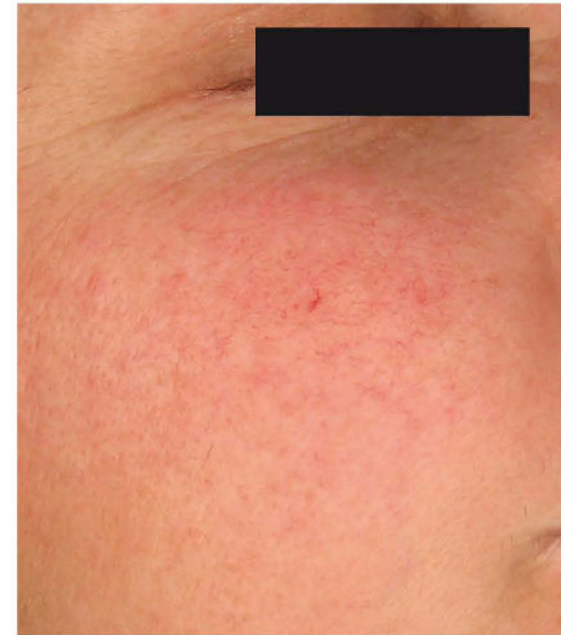50-years old
Caucasian female

Phototype II

Nr. of treatments: 2



*Before the treatment
(picture taken using polarized light)*



*Thirty days after the 2nd treatment
(picture taken using polarized light)*

Courtesy of

P. Bonan, MD – P. Campolmi, MD – G. Cannarozzo, MD

Department of Dermatology. University of Florence, Italy

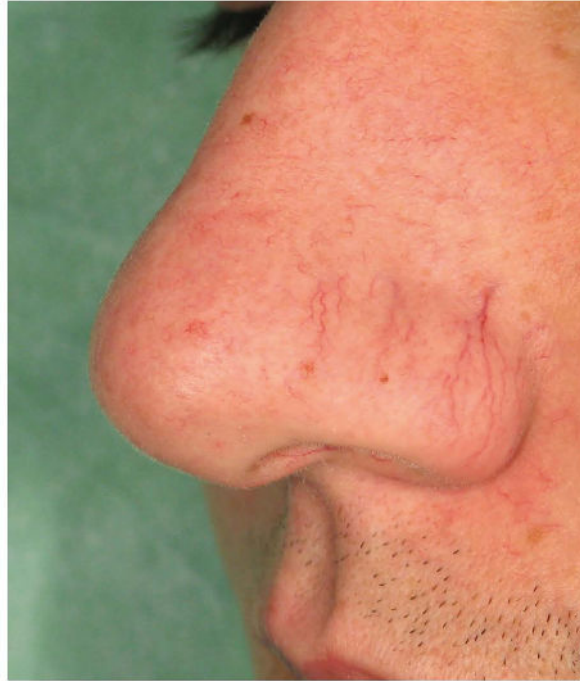Vascular Lesions – Nd:YAG

Nose Teleangiectasias

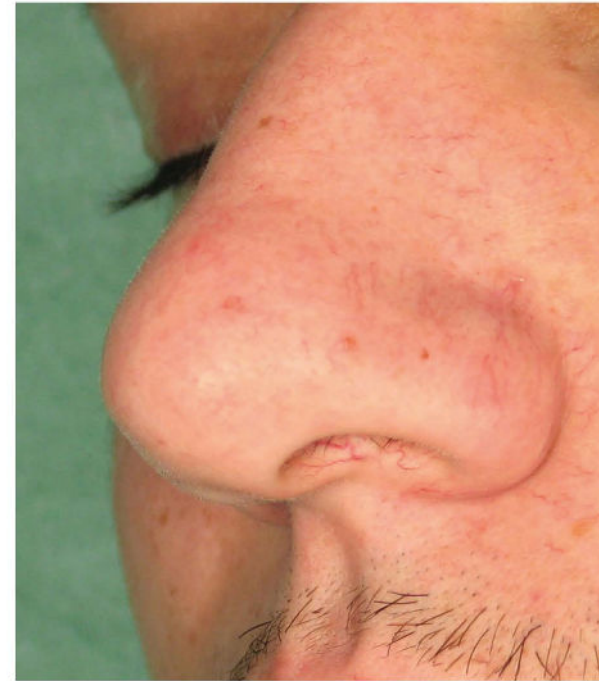25-years old
Caucasian male

Phototype II

Nr. of treatments: 1



*Before the treatment
(picture taken using polarized light)*



*Twenty days after a single treatment
(picture taken using polarized light)*

Courtesy of

P. Bonan, MD – P. Campolmi, MD – G. Cannarozzo, MD

Department of Dermatology. University of Florence, Italy

Vascular Lesions – FT Pulsed Light

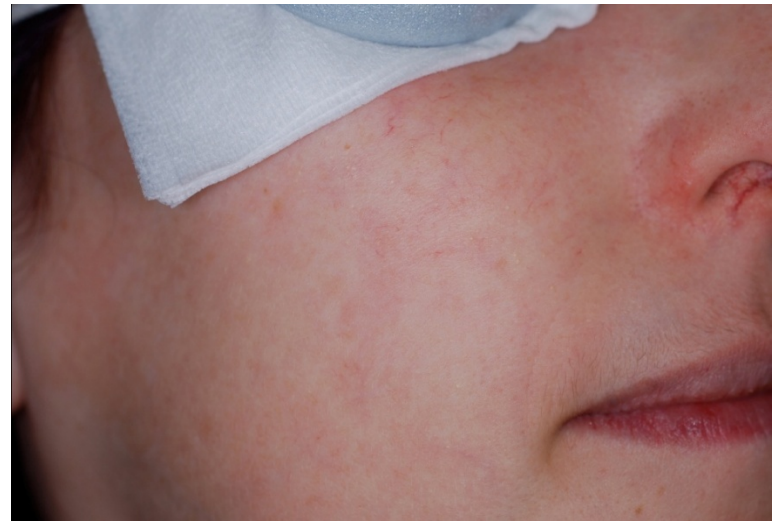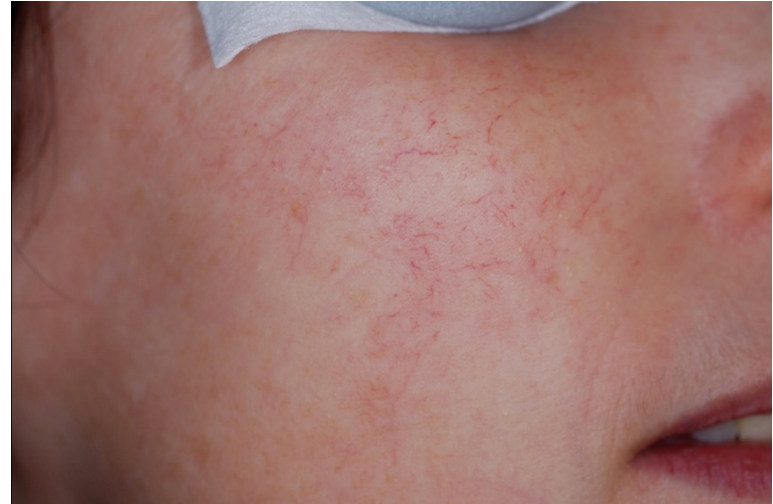Couperose

Caucasian female

Phototype III

Nr of treatments: 1

Nr of passages: 1



Courtesy of M. Patarin, MD - Challans, France.

MEDICINE AND AESTHETICS

Benign Pigmented Lesions – FT Pulsed Light

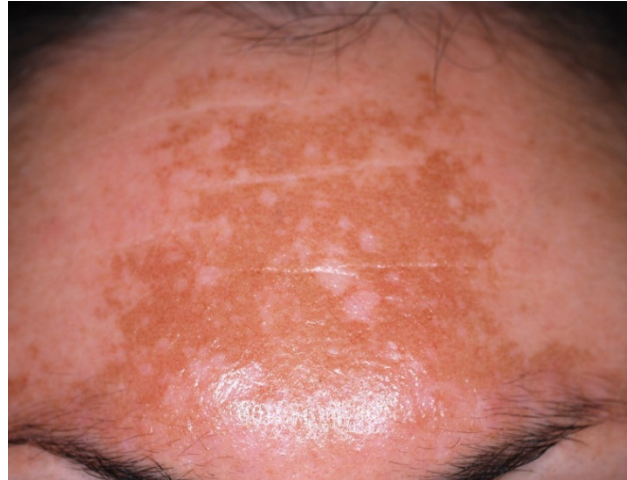Melasma

Caucasian female

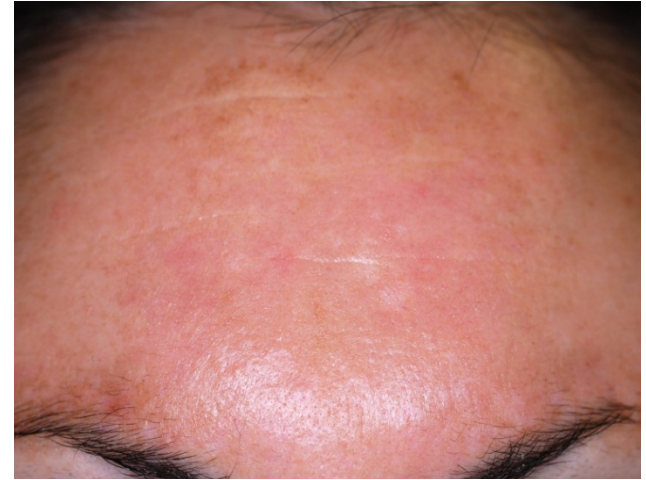Phototype III

Nr of treatments: 1

Nr of passages: 2



Before.



6 days after the treatment.

Courtesy of M. Patarin, MD - Challans, France.

Benign Pigmented Lesions – FT Pulsed Light

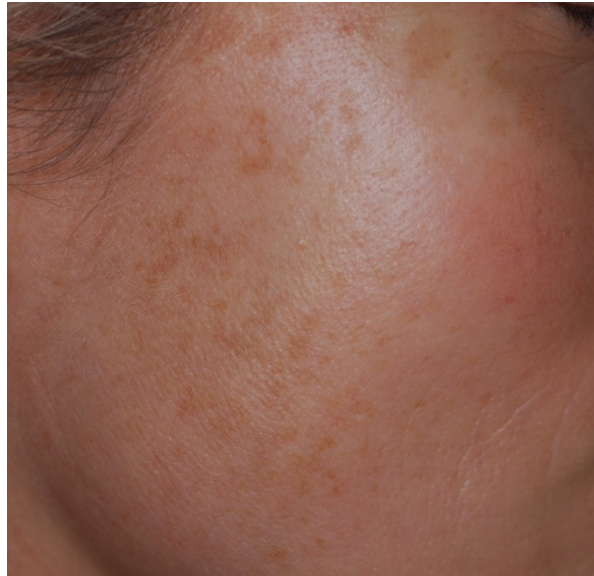Melasma

Caucasian female

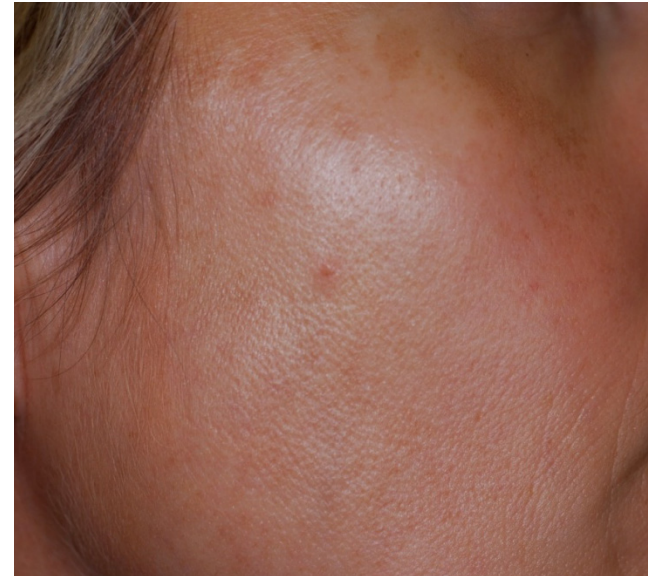Phototype II

Nr of treatments: 2

Nr of passages: 2



Before.



After.

Courtesy of M. Patarin, MD - Challans, France.

Benign Pigmented Lesions – FT Pulsed Light

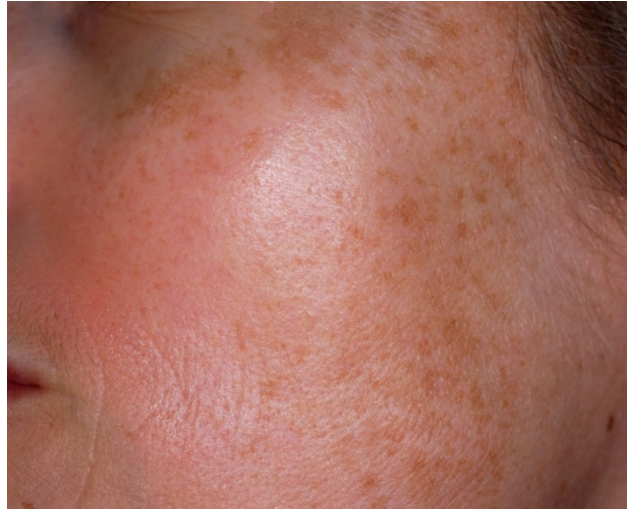Melasma

Caucasian female

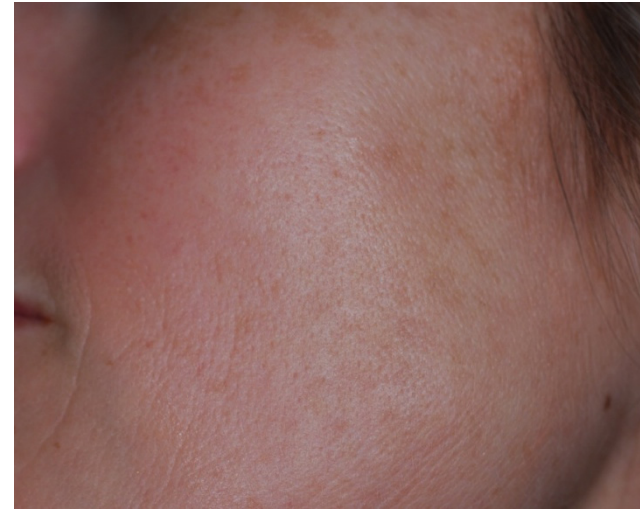Phototype II

Nr of treatments: 2

Nr of passages: 2



Before.



After.

Courtesy of M. Patarin, MD - Challans, France.

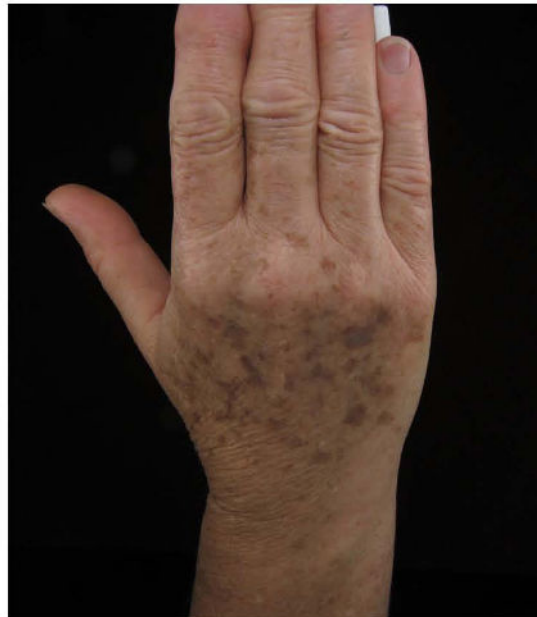Photorejuvenation – FT Pulsed Light

Hand Dyschromias

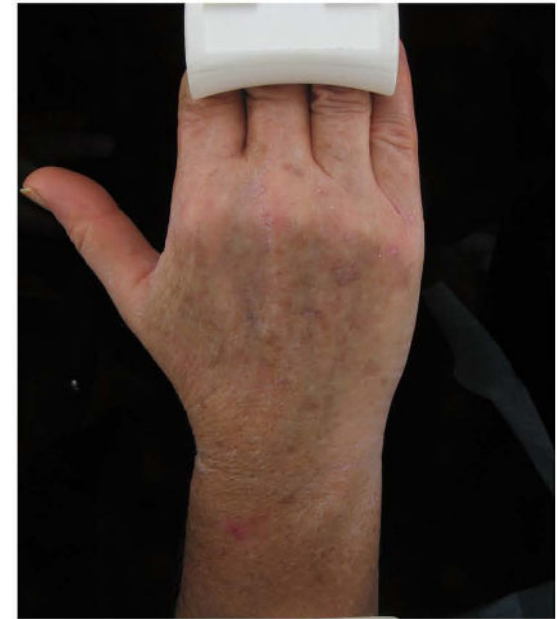Caucasian female

Phototype II

Nr of treatments: 3



Before the treatment



One week after the 3rd treatment

Courtesy of
A. Pulvirenti, MD. Aging Medicalaser. Catania, Italy.

MEDICINE AND AESTHETICS

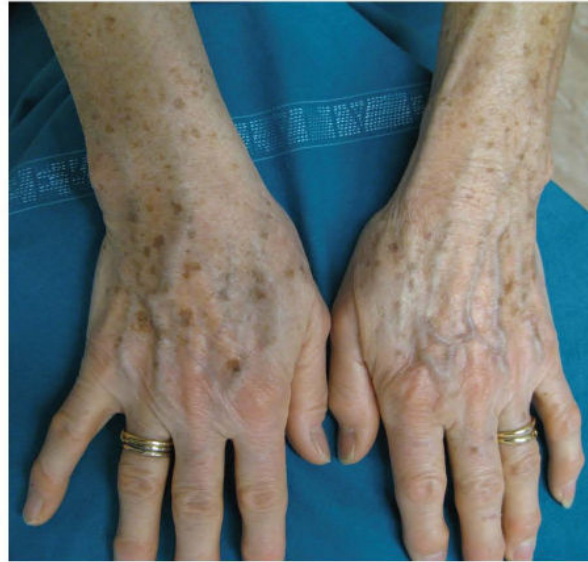Photorejuvenation – FT Pulsed Light

Hand Dyschromias

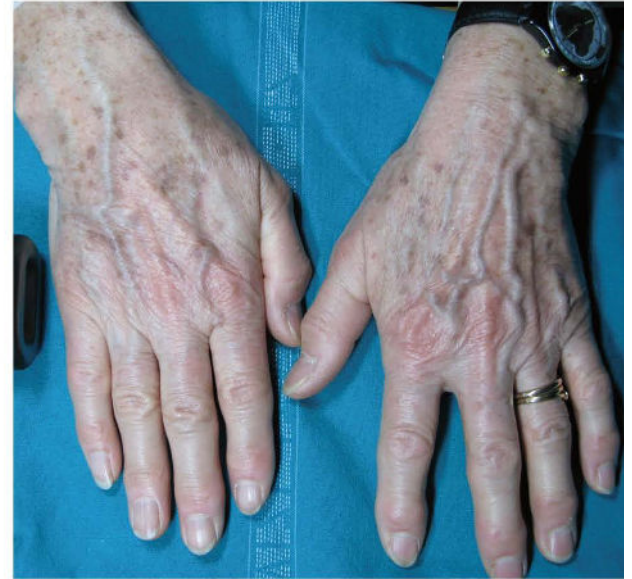Caucasian female

Phototype II

Nr of treatments: 4



Before the treatment



One month after the 4th treatment

Courtesy of

P. Bonan, MD – P. Campolmi, MD – G. Cannarozzo, MD

Department of Dermatology. University of Florence, Italy

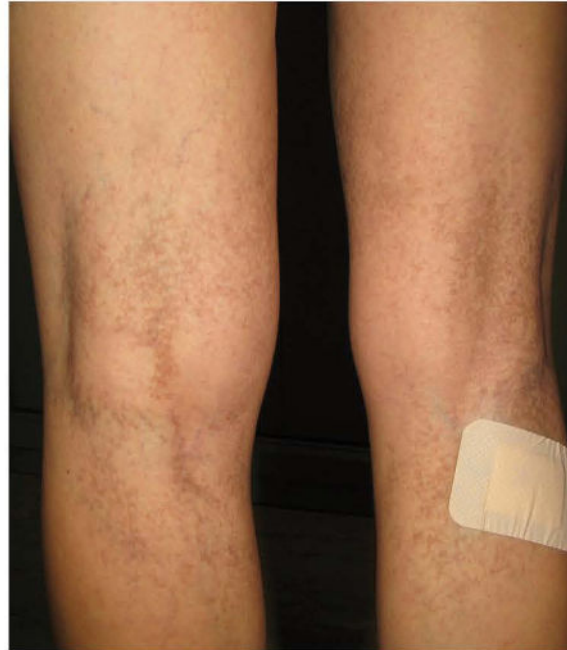Benign Pigmented Lesions – FT Pulsed Light

Pigmented Angiodermia (Lower Limbs)

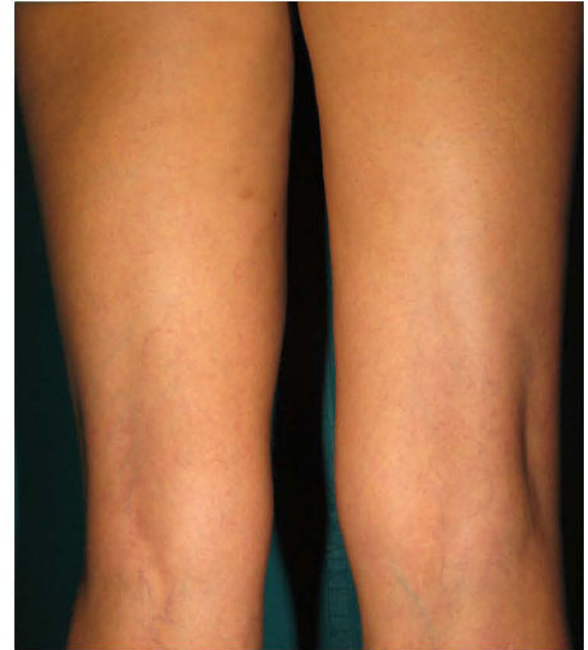40-years old
Caucasian female

Phototype III

Nr of treatments: 6



*Before the treatment
(picture taken using polarized light)*



*Five months after the 6th treatment
(picture taken using polarized light)*

Courtesy of

P. Bonan, MD – P. Campolmi, MD – G. Cannarozzo, MD

Department of Dermatology. University of Florence, Italy

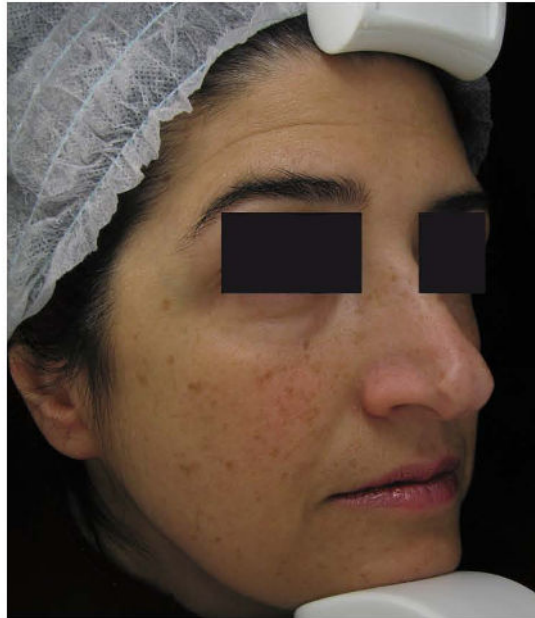
Photorejuvenation – FT Pulsed Light

Mixed Facial Photorejuvenation

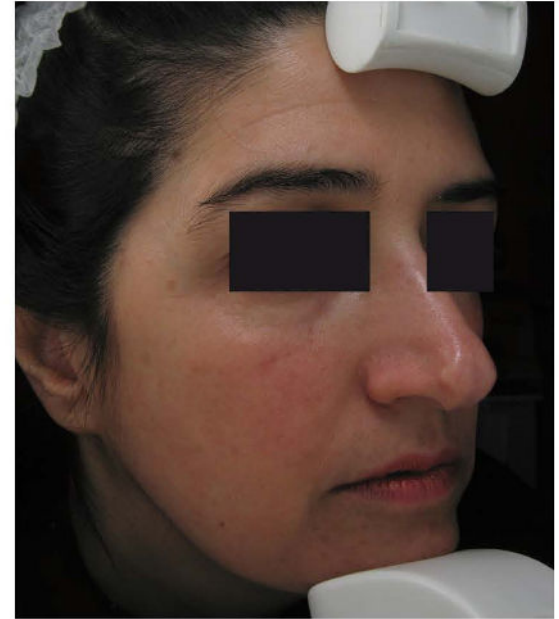Caucasian female

Phototype III-IV

Nr of treatments: 3



Before the treatment



One week after the 3rd treatment

Courtesy of
A. Pulvirenti, MD. Aging Medicalaser. Catania, Italy.

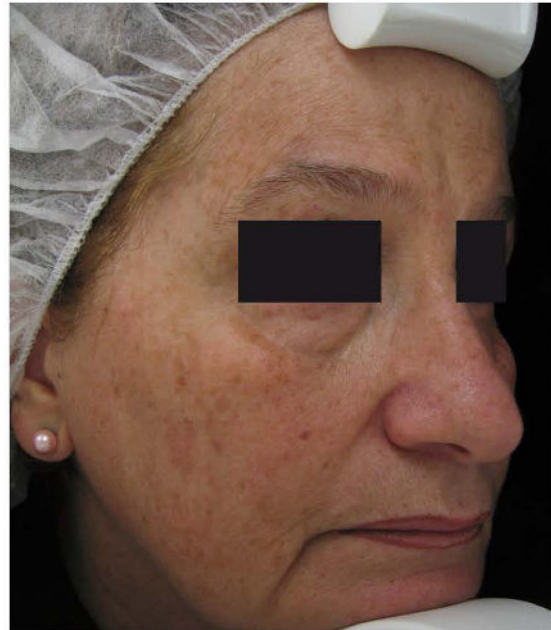Photorejuvenation – FT Pulsed Light

Pigmented Facial Photorejuvenation

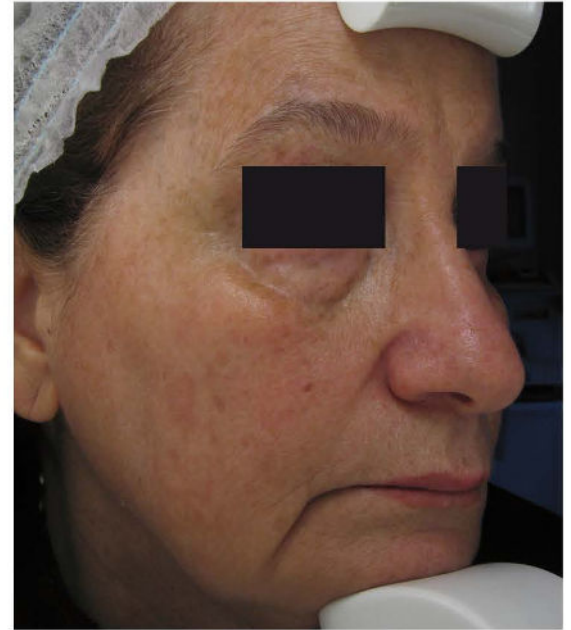Caucasian female

Phototype II

Nr of treatments: 2



Before the treatment



One week after the 2nd treatment

Courtesy of
A. Pulvirenti, MD. Aging Medicalaser. Catania, Italy.



The Code of Excellence

THANK YOU FOR YOUR ATTENTION

© Deka M.E.L.A. Srl, 2010

All rights reserved. All other brands and product names are trademarks or registered trademarks of their respective holders.

MEDICINE AND AESTHETICS