

## ORIGINAL ARTICLE

# Efficacy and safety evaluation of an innovative CO<sub>2</sub> laser/radiofrequency device in dermatology

P. Campolmi, P. Bonan, G. Cannarozzo, N. Bruscino,\* S. Moretti

Department of Dermatology II, University of Florence, Florence, Italy

\*Correspondence: N. Bruscino E-mail: bruscino@alice.it

## Abstract

**Background** CO<sub>2</sub> laser has not only become the most widely used laser in dermatological surgical practice, but it has also proved to be highly effective in treating aesthetic imperfections.

**Objective** To examine the efficacy and safety of a novel fractional CO<sub>2</sub> laser combined with a radiofrequency device in different dermatological, surgical and aesthetic fields.

**Methods** A total of 79 patients were treated in our Outpatient Service with a novel fractional CO<sub>2</sub> laser combined with a bipolar radiofrequency device for a maximum of 5 months. Group A consisted of 39 patients with lesions requiring complete excision, whereas Group B consisted of 40 subjects seeking to enhance aesthetic facial imperfections. The results were assessed by three 'blind' investigators using photographs and clinical observations; in addition, the patients had to give their own subjective assessment of the results.

**Results** At the 6-month follow-up, the lesions of the Group A patients had been completely removed, except for one case of a large sebaceous nevus on the scalp. All the Group B patients showed global improvement in skin tightening, removal of fine lines and rhytides and correction of dilated pores and hyperpigmentation, with no significant side-effects and short downtimes.

**Conclusion** This kind of laser meets the needs of the majority of dermatologists requiring a unique, versatile tool to remove cutaneous lesions and at the same time, safely and effectively treat skin imperfections.

Received: 14 May 2012; Accepted: 03 Oct 2012

## Conflict of interest

None Declared.

## Funding sources

None Declared.

## Introduction

Laser techniques have become a powerful and indispensable instrument in dermatology. The carbon dioxide (CO<sub>2</sub>) laser has been used extensively in dermatological surgery over the past 30 years and is now recognized as the gold standard for vaporizing the soft tissues. Over the last decade, an increasing demand for skin rejuvenation treatments has made it possible to treat many purely aesthetic skin and mucosa lesions more safely and effectively. CO<sub>2</sub> laser has not only become the most widely used laser in dermatological surgical practice<sup>1–8</sup>, but it has also proved its effectiveness in treating aesthetic imperfections. Fractional photothermolysis has recently been introduced in laser technology, giving rise to new applications of CO<sub>2</sub> laser.<sup>9–13</sup> It was developed by Mainstein<sup>14</sup> in 2004 for non-ablative lasers and therefore applied to ablative lasers like the CO<sub>2</sub> (10600 nm), Er:YAG (2940 nm) and Er:YSGG (2790 nm). The use of the fractional CO<sub>2</sub>

laser technique usually results in faster healing and reduced downtime, minimizing any side-effects.<sup>15–19</sup> The latest challenge has been the diversification of the choice of pulses for ensuring accurate pulse shape management. With this strategy, more effective and varied biological effects can be induced in the tissue, stimulating the dermis to produce new collagen, naturally regenerating the texture and enhancing skin tone and softness.<sup>20</sup> For the last 5 years, bipolar radiofrequency devices have been considered non-invasive instruments, able to stimulate the deeper dermis in a non-ablative manner.<sup>21–28</sup> Nowadays, only a few devices combine the effect of radiofrequency with laser or light energy in a unique tool capable of targeting lesions requiring surgical ablation, as well as aesthetical imperfections such as fine lines, wrinkles, pigment alterations, and skin laxity that have to be reduced or completely removed. The purpose of our study is to examine the efficacy and safety of this novel device combining fractional CO<sub>2</sub> laser and ra-

diofrequency in different fields of dermatological, surgical and aesthetic treatment.

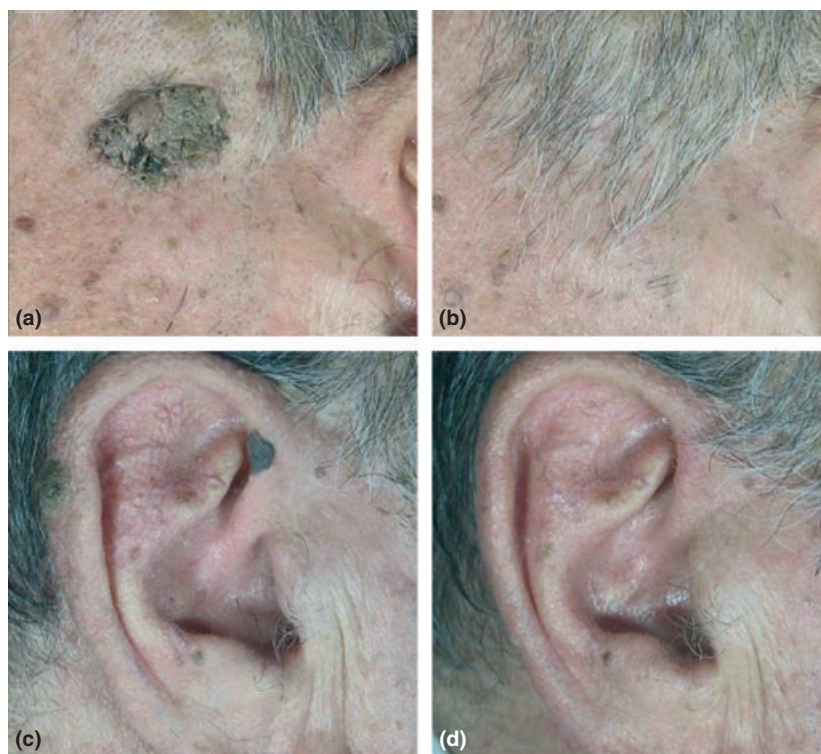### Material and methods

A total of 79 patients, 52 women and 27 men, mean age 61.2 (range 37–75 years), Fitzpatrick skin types I–IV, mainly I–II, were treated in our Outpatient Service using SmartXide<sup>2</sup> DOT/RF (DEKA-M.E.L.A., Calenzano, Italy) for a maximum of 5 months. The study design was approved by the local Institutional Review Board in compliance with the Helsinki Declaration, and the patients were enrolled after obtaining a detailed personal history (skin type, clinical symptoms, health conditions, previous medications, life-style) and informed consent for treatment. The patients were divided into two groups, A and B.

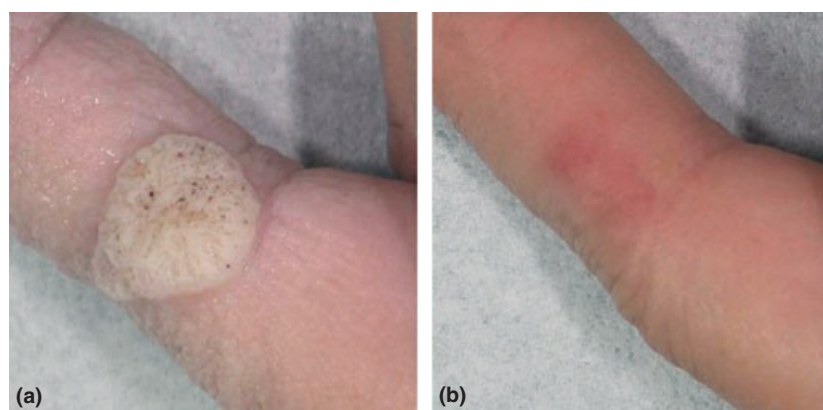
#### Group A

Group A consisted of 39 patients, 19 women and 20 men, mean age 62.4 (range 37–73 years), Fitzpatrick skin types I–IV. Group A patients had different kinds of lesions that had never been treated before and were located on the face, trunk, arms, legs and several other body areas. The number of lesions, 51, was higher than the number of patients, 39, as some had several lesions. In all there were nine seborrheic keratoses (Fig. 1a–c), 7 actinic keratoses,

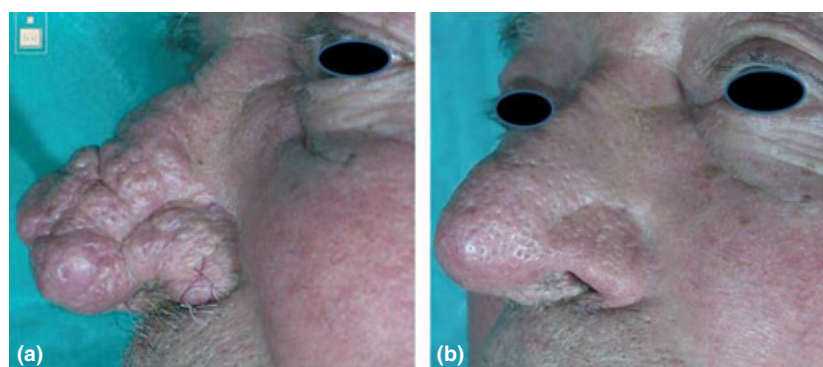
five warts (Fig. 2a), five facial milia, four xantelasmas, four rhynophimas (Fig. 3a), three epidermal nevi, three condylomas (Fig. 4a–c), two skin neurofibromas, three sebaceous nevi (Fig. 5a), two syringomas, two nodular chondrodermatitis of the ear's helix, one actinic cheilitis, and one molluscum contagiosum. The inclusion criteria for this technique were no administration of anticoagulants for 7 days previously, no administration of oral retinoid drugs for at least 8 months previously, no previous treatments, absence of a positive anamnesis for the formation of keloids or collagenopathies. The majority of the lesions were treated without anaesthesia and a dynamic cooling system with a jet of cool air was used during the sessions to reduce any discomfort. We limited the use of anaesthesia because our series patients were able to tolerate the procedure without analgesia, and also because local injections of an anaesthetic could cause oedema and hinder the 'visual feedback processing' during treatment. With 'visual feedback processing' we are able to identify the skin layer reached by CO<sub>2</sub> laser ablation, observing the specific features of skin colour and texture during the procedure, whereas by injecting an anaesthetic, the perception of the layer reached may be modified. The typical cutaneous markers notable during CO<sub>2</sub> laser ablation are an opalescent aspect for epidermis, a flat, smooth, and pink surface for the papillary derma, a hardened yellowish tissue similar



**Figure 1** (a) A  $2.4 \times 1.8$  cm seborrheic keratosis localized in the temporal area. (b) The disappearance of the lesion in (a), 6 months after the first and only laser session. (c) Two seborrheic keratoses localized on different parts of the helix, right ear. (d) Helix of the same ear in (c), at 6-month follow-up after the first and only laser treatment.



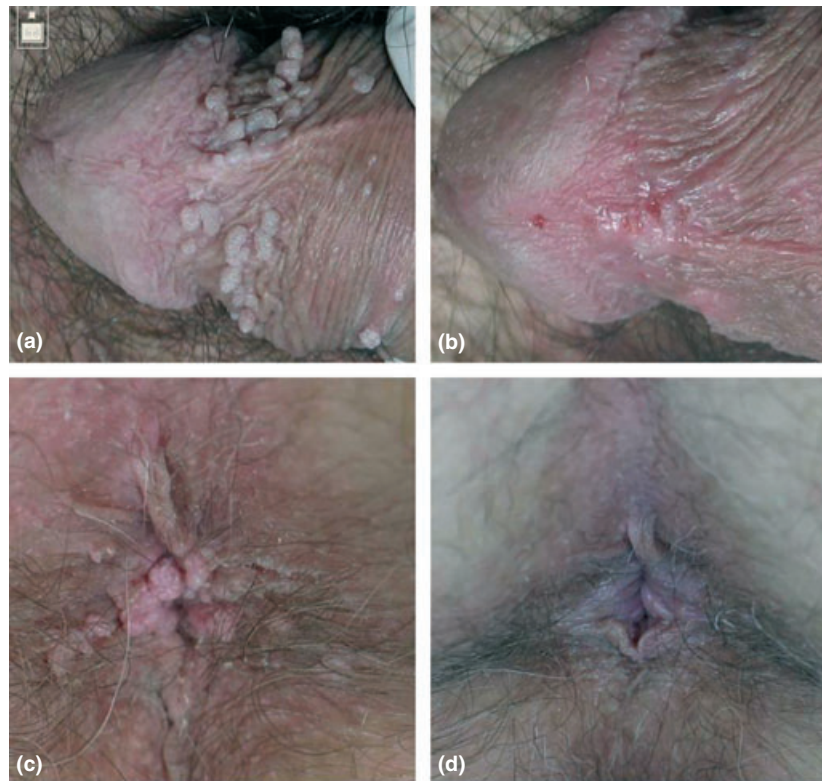**Figure 2** (a) A 1.5 × 1.3 cm wart on the second finger of the left hand. The wet area is due to the use of a eutectic mixture of lidocaine 2.5% and prilocaine 2.5% in an oil-in-water emulsion. (b) At the 6-month follow-up after the first and only laser application the lesion had disappeared, leaving mild erythema.



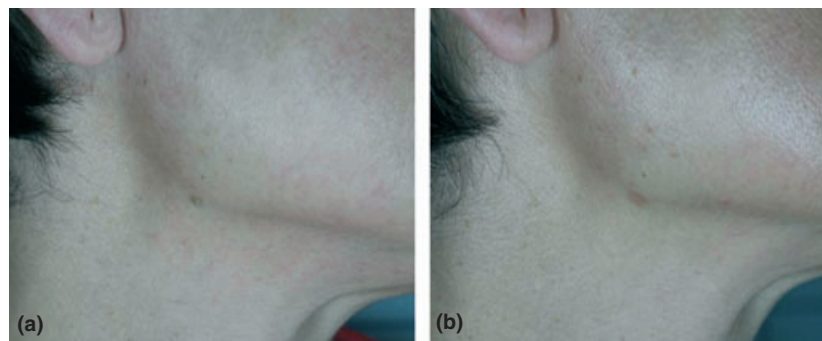**Figure 3** (a) A rhinophyma previously treated unsuccessfully with oral isotretinoin and dermabrasion. (b) At the 6-month follow-up after the third laser treatment, a marked improvement of the rhinophyma can be observed.

to 'chamois skin' for the superficial derma, while the vaporization of the reticular derma reveals large collagen fibre fascias that in macroscopic terms look like 'waterlogged cotton threads'. The use of anaesthesia depended upon the site and type of lesion and the settings required to remove it. Only for the more challenging and sensitive areas, such as around the eyes, the oral and anal areas, genital mucosa and fingers, was a local injection of mepivacaine chloridrate 1% (Mepivacaina Angelini®, ACRAF, Roma) necessary in four patients. In other eight cases, we applied a eutectic mixture of lidocaine 2.5% and prilocaine 2.5% in an oil-in-water emulsion, which was removed immediately before beginning treatment. The patients were treated for a maximum of 2 months and received from one to three laser applications (SmartXide<sup>2</sup> DOT/RF) at 3–4-week intervals. We applied CO<sub>2</sub> laser with a super rather than a continuous pulse mode for the majority of lesions for ensuring that the zones were always treated at the desired level of thickness. We operated with a power range of 0.1–1 W and a frequency of 10 Hz; only occasionally was the power increased to 2 W and the

frequency to 20 Hz for treating the more difficult lesions. The choice of the appropriate parameters depended on the size, anatomical localization, and other features of the lesion to be treated, e.g. with plantar warts we used a 10–15 W power in continuous mode, and a 50–100 HZ frequency with 6–10 W power also in continuous mode for large rhinophymas. Moreover, the dermatologist was able to exploit an innovative system called Pulse Shape Design that offers a range of pulses to choose from: S-pulse, D-pulse and H-pulse, all characterized by different pulse features and therefore with different biological effects on the tissue. After the sessions, we recommended the application of topical antibiotics (Gentalyn® ointment 30 g 0.1, Schering Plough, Kenilworth, NJ, USA) on the lesion covered by a non-occlusive dressing (Tegaderm®, 3M Health Care, St. Paul, MN, USA) or in some cases, especially bald areas, face and other photoexposed areas, we used a hydrocolloid transparent dressing (Comfeel®, Coloplast, Peterborough, UK), which is permeable to water vapour but impermeable to exudate and microorganisms and ensures high



**Figure 4** (a) Multiple condylomas of the preputio-glandular area. (b) The same patient as in (a), with no more visible lesions after two lasers sessions and no recurrences at the 6-month follow-up. (c) Multiple perianal acuminate condylomas. (d) The condylomas in (c) were removed after two laser applications with no reappearance of the same lesions at the 6-month follow-up.



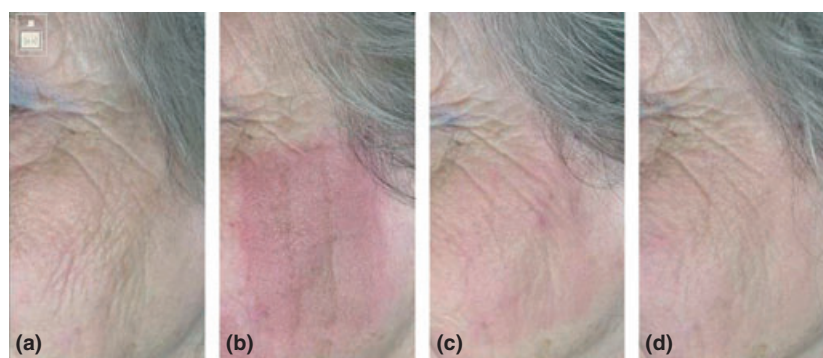
**Figure 5** (a) Nevus sebaceous of the right mandibular region. (b) Successful removal of the lesion at the 6-month follow-up, absent on palpation, but with slight hyperpigmentation persisting due to the high phototype of the patient and inadequate sunscreen protection by patient.

absorbency and correct management of wound exudate and skin secretions. The transparent dressing facilitated inspection of the wound without being removed, enabling close monitoring of the healing process. The patient had to remove the patch/transparent dressing each day, wash the wound with a cleansing foam and then reapply the dressing/patch for 1–2 weeks, without inducing the crust, and protecting the wound with sunscreens.

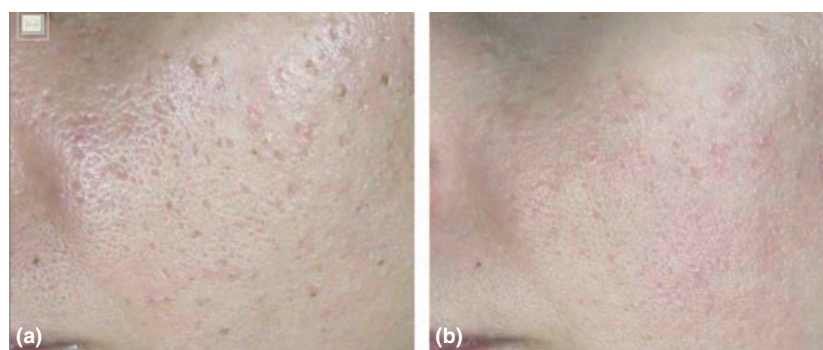#### Group B

Group B consisted of 40 subjects, 33 women and seven men, mean age 59.3 (range 43–75 years), Fitzpatrick skin types I–III. These patients showed the typical hallmarks of facial ageing including expression lines, rhytides, wrinkles (Fig. 6a), dilated pores (Fig. 7a), skin laxity, and yellowish/grey superficial hyperpigmentation (Fig. 8a). The inclusion criteria for this technique were no

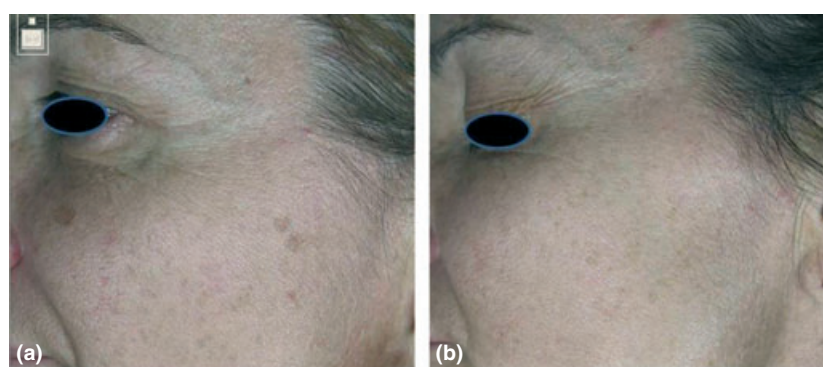




**Figure 6** (a) The left cheek of a 69-year-old patient with marked signs of ageing, particularly lines and wrinkles. (b) The typical erythema appeared after the first laser treatment. It is easy to note the single DOTs and network due to the 'overlapping effect'. (c) After four laser applications, most of the wrinkles and the rhytides on the cheek have disappeared. (d) At the 3-month follow-up, there was a marked improvement in the texture with increased skin smoothness. Clinical differences are evident compared to the untreated area around the eyes.



**Figure 7** A The left cheek of a 43-year-old female patient with visibly dilated pores. B. After three laser sessions, most of the pores have disappeared or been reduced in size, with improved smoothness of the skin in that area.



**Figure 8** (a) Other typical hallmarks of ageing with hyperpigmentation on the left cheek. (b) After four laser treatments the patient's previous hyperpigmentation had disappeared; at the 3-month follow-up there were no recurrences.

topical exfoliant treatments for at least 2 months previously, no administration of photosensitizing or oral retinoid drugs for at least 8 months previously, no surgical treatments or local injection

therapies for 8 months previously, no photorejuvenation treatments with other sources or photodynamic therapy with 5-amino-levulinic acid for at least 1 year. Patients with a positive anamnesis

for the formation of keloids or collagenopathies were excluded. In particular six patients had received previous fractional CO<sub>2</sub> rejuvenation more than a year before. In 13 cases, after removing make-up, an anaesthetic cream was applied 15–20 min before treatment to achieve more positive patient compliance; we preferred the application of a eutectic mixture of lidocaine 2.5% and prilocaine 2.5% in an oil-in-water emulsion, which was removed immediately before beginning treatment. A dynamic cooling system with a jet of cool air was always used during the sessions to reduce any discomfort. The patients received from three to five treatments to photo-damaged facial skin at 4–6-weekly intervals using the SmartXide<sup>2</sup> DOT/RF laser device (DEKA-M.E.L.A., Calenzano, Italy). Each treatment session entailed one pass only per area with numerous successive and consecutive pulses in the same point (DOT) without moving the scanner ('scalpel effect') and using the 'Pulse Stacking' function. The settings included 8–15 W, 500–750 µm DOT spacing, 500–1200 µs dwell time, up to two stacking. The therapeutic sessions entailed the combined effects of radiofrequency and laser applied simultaneously. The bipolar radiofrequency settings were 20–30 W, 2–3 s. At the end of the treatment, compression was maintained for approximately 20 min with gauze soaked in saline solution, followed by the application of a moisturizing cream. Patients were instructed to avoid the sun and cosmetics during the immediate postprocedural periods and to apply cool compresses, emollient creams and sunscreens until complete re-epithelization. An antibiotic ointment and an anti-herpetic cream were also applied to the target areas from 2 days before treatment up to 7 days after each laser session, as herpetic and bacterial complications are possible in the absence of appropriate pre- and posttreatment care.

### Clinical evaluation

Photographs were taken using a Canon digital camera and a polarized flash (Anthology system, DEKA-M.E.L.A., Calenzano, Italy), before and after each treatment and at the 4-week, 3-month and 6-month follow-ups after the final treatment. The photos were standardized using the same camera, setting, twin flash, ambient light and chin holder to guarantee the same distance. Three 'blind' observers who had not taken part in the treatments assessed the photos at the 6-month follow-up for lesion removal and possible recurrences in group A patients, for whom the device was used as an ablative tool. In addition, group A patients were placed in front of a mirror and asked for a subjective evaluation of the perceived overall results by means of the following score: unsatisfied, not very satisfied, satisfied, very satisfied.<sup>29</sup> The results of group B were judged by the same 'blind' investigators at the 3-month follow-up; they assessed the performance of this device by ranking the results in four categories (quartiles) of skin tightening improvement, fine line and rhytide clearance, hyperpigmentation correction and overall skin flabbiness and texture: 1 = no or poor results (0–25%), 2 = slight improvement (25–50%), 3 = moderate improvement (50–75%) and 4 = marked improvement (75–100%).

A subjective evaluation of the results was also conducted among the B group patients.<sup>29</sup>

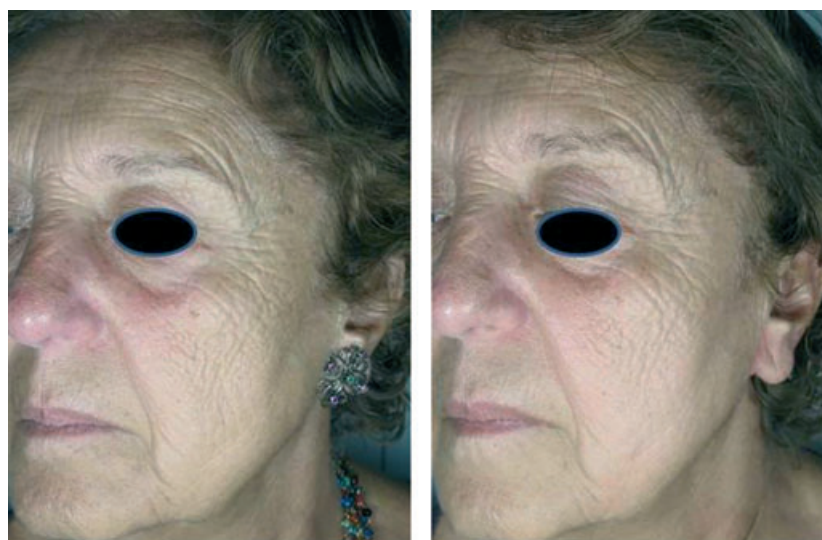## Results

### Group A

At the 6-month follow-up after the last laser session the three investigators noted a marked improvement in the clinical conditions of group A patients (Figs 1b–d, 2b, 3b, 4b–d), as all the lesions had been completely removed except in the case of a large sebaceous nevus on the scalp: this recurrence only appeared after the 6-month follow-up. A total of 21 patients (53.8%) were very satisfied, 14 (35.9%) were satisfied (Fig. 5a–b) and 3 (7.7%) were not very satisfied with the results, whereas only one patient (2.6%) was unsatisfied due to the recurrence of the lesion. The poor satisfaction in three subjects was probably linked to the onset of eczematous erythema with vesicles following contact sensitization to the topical antibiotic (Gentalyn<sup>®</sup> ointment), the patch (Tegaderm<sup>®</sup>) or the hydrocolloid transparent dressing (Comfeel<sup>®</sup>). The re-epithelization started a few days after laser treatment and was completed within 1–2 weeks. The downtimes were between 3 and 7 days in nearly all patients, and the erythema normally never lasted longer than 7 days. Oral administration of NSAIDs was helpful in two cases of intense erythema and oedema, repeated by these patients at home for the following 4 days. No major complications were observed, such as bacterial infection or scarring in any of the patients.

### Group B

All the patients in Group B showed global improvement in skin tightening, clearance of fine-lines and rhytides (Fig. 6d) and correction of dilated pores and hyperpigmentation (Figs 7b and 8b): 11 patients (27.5%) achieved marked improvement, 19 patients (47.5%) moderate improvement, seven patients (17.5%) slight improvement and three subjects (7.5%) poor or no improvement. Sixteen patients (40%) were very satisfied, 17 (42.5%) were satisfied and 4 (10%) were not very satisfied, whereas only three patients (7.5%) were unsatisfied with the results; the four cases of poor satisfaction were due to erythema from the use of higher parameters, which prevented them from returning to public life as early as desired; the three other patients were unsatisfied because the results failed to meet up to their expectations. This is typical of patients with signs of severe facial ageing for which very low parameters were used (Fig. 9a,b). Immediately after the sessions, the majority of patients showed signs of erythema and oedema (Fig. 6b), more evident in the area around the eyes. On the second or third day, there were cases of colour change (tanned appearance) followed by mild peeling. Once the skin had stopped peeling, there were varying degrees of long-lasting erythema. Despite a few predictable side-effects such as redness, swelling, crusting, mild pruritis and discomfort, there were no serious adverse effects (e.g. hyperpigmentation, hypopigmentation,



**Figure 9** (a) Patient with severe signs of facial ageing. (b) Result after three treatments with very low parameters.

blisters, scars or posttreatment infections) in any of the patients who were therefore very satisfied, especially in view of the clinical outcome (Figs. 6c,d).

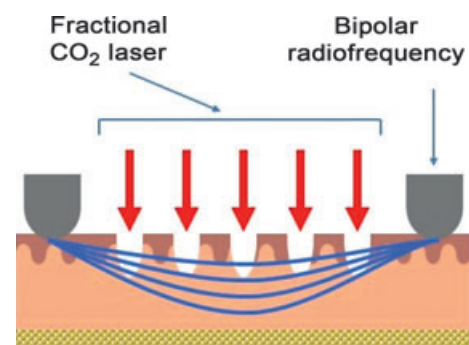
### Discussion

CO<sub>2</sub> laser systems enable precise, efficacious and targeted thermal action on the lesions treated, at the same time protecting the adjacent areas and thus guaranteeing optimal re-epithelization. This makes it suitable for surgical procedures as the limited inflammatory response is conducive to better healing.<sup>1–8</sup> The extreme precision of the application means that the epidermis alone can be vaporized, or the thermal effect can be extended even deeper into the papillary or reticular derma. The use of 'colour indicators' allows for step-by-step visual assessment of the level reached and an accurate calculation of the clinical 'end-point' phase. The versatility of the device is also guaranteed by the innovative Pulse Shape Design system which enables the selection of different kinds of pulses (S-pulse, D-pulse and H-pulse) for inducing different biological effects in the skin tissue. The S-pulse which has a more circular ablative shape, operates selectively on the papillar dermis. The D-pulse mainly acts as deep as the reticular dermis, inducing greater shrinkage and more effective coagulation. The H-pulse is used especially when the dermatologist requires increased emission power compared with the S-pulse and D-pulse. This pulse mode is very useful for obtaining fast and delicate ablation, acting in a similar manner to the Er:YAG laser, while conserving the typical skill of the CO<sub>2</sub> laser with its coagulating effect. During the group A treatments, the sessions started with high parameters, corresponding to a deeper skin ablation effect, for the 'rough-shape' phase. After the initial procedure, the parameters were reduced to perform more precise 'final touches'. In particular, we started with either S-pulse or D-pulse

mode, representing typical CO<sub>2</sub> ablation, and completed the session with the H-pulse to provide the lesion with a more precise finish. In our laser experience, depending on the pulse shape design, a significant reduction in the pulse heat is able to ensure more delicate ablation. Even extremely superficial vaporization is therefore possible with greatly reduced downtimes and fewer undesirable side-effects (e.g. dyschromia and atrophy). Other advantages of this novel CO<sub>2</sub> laser approach include less need for anaesthesia and reduced thermal damage, consequently with less bleeding and less inflammation. These benefits should be compared with other techniques such as diathermocoagulation and traditional surgery, which on the contrary, usually involve anaesthesia, longer downtime, slower cicatrization and a higher incidence of hypertrophic scars and keloids. Another significant limitation of these two surgical treatments is their difficulty in accessing hard-to-reach areas such as the inner corners of the eyes, the ears, the nasal alae, and the genitals. Instead, this CO<sub>2</sub> laser device also facilitates the removal of lesions from anatomically challenging areas as well as other delicate areas such as the mucosa and pseudomucosa. We consider this laser approach particularly suitable for the mucous and pseudomucous membranes (e.g. the oral cavity, lips, anal area, and genitals), in view of the reduction of the corneal layer and the high content of water in these sites which make this technique so efficacious. In our experience with the CO<sub>2</sub> laser, anaesthesia is never used with powers lower than 1–2 W and a frequency of 10–20 Hz, even though this also depends on the site, type and level of the lesions. Local anaesthesia is only applied when we treat more difficult and sensitive body areas (e.g. the area around the eyes, oral and anal areas, genital mucosa, and fingers). The use of anaesthesia is not usually necessary because our patients are able to tolerate the procedure without analgesia, and also because injective local anaesthesia can

cause oedema and hinder the 'visual feedback processing' during treatment. In some cases we suggest the application of an eutectic mixture of lidocaine 2.5% and prilocaine 2.5% in an oil-in-water emulsion (Fig. 2a), especially for small and superficial lesions. The use of a topical anaesthetic like lidocaine and prilocaine in an emulsion often decreases the effectiveness of the CO<sub>2</sub> laser, because the layer of liquid emulsion found between the laser and the target tissue reduces the ablative laser effect; for this reason dermatologists must ensure that the tissue surface is completely dry before operating with CO<sub>2</sub> lasers. This laser technique has also been used in the field of aesthetic medicine, exploiting its thermal rather than its vaporizing effects. Ablative resurfacing with CO<sub>2</sub> laser has been considered the gold-standard for treating wrinkles, skin damage from photoageing and postacne scars;<sup>9–19</sup> however, this method was also associated with lengthy downtimes, occasional bacterial and viral infections, and bothersome side-effects such as persistent erythema, postinflammatory pigmentation alterations and possible atrophic scarring. The excellent results obtained with this technique have therefore stimulated research into methods and technologies capable of achieving similar results while reducing downtimes and side-effects. Based on these requirements, 'fractional' resurfacing with CO<sub>2</sub> laser, which combines laser energy with bipolar radiofrequency has been developed. This fractional CO<sub>2</sub> laser (SmartXide<sup>2</sup> DOT/RF) is equipped with a new scanning system (HiScanDOT/RF) which makes it possible to obtain vertical microcolumns of damage, microablative and microthermal zones (MAZs and MTZs), surrounded by areas of healthy tissue. Depending on the pulse used, the controlled release of heat in the treated microareas has an immediate tissue-shrinking effect and generates the stimulation of growth factors, wound repair and the reorganization of new collagen.<sup>30</sup> Another feature which increases the versatility of this application is the possibility of selecting the distance (DOT spacing) between surrounding MAZs and MTZs, providing a resurfacing effect similar to the ablative technique with reduced spacing, or the more typical fractional effect, with greater spacing between DOTs. The versatility of this device also derives from the 'Smart Pulse mode', a function that allows physicians to obtain two different effects in the target area to be treated, depending on the patients needs and the type of treatment required, namely, 'the ablative effect' and the 'thermal effect'. The first, which depends mainly on the power (Watts) is achieved with a fast release of high energy to the tissue causing rapid ablation of the epidermis and more superficial dermal layers. Instead, the 'thermal effect' depends mainly on the dwell time ( $\mu$ s) during which the heating of the deeper layers of the skin spreads to the surrounding areas and deeper areas of the microthermal zone (MTZ), continuing the laser effect. Another important function that we used in this study is the novel 'Pulse Stacking mode'. Each treatment session consisted of numerous successive and consecutive pulses (1–5) in the same point without moving the scanner ('scalpel effect'). This function allows deeper penetration thanks to the possibility of

repeating the laser emissions with the same parameters on one DOT before moving on to the next DOT during the same scanner passage.<sup>20</sup> With the fractional CO<sub>2</sub> treatment, the epidermis receives a sort of microablation and heals in 24–48 h: the epidermal tissue recovery occurs rapidly via keratinocyte migration and extrusion of the damaged cells to the borders of the ablative and thermal zones; the keratinocyte migration occurs thanks to the presence of 'a reservoir' of partially differentiated cells with a high turnover and high mitotic index that are able to repair the tissue deprivation; the epidermal stratus corneum acts as a natural bandage that protects the tissue from noxious external factors while the treatment effects continue in the deeper dermis.<sup>31,32</sup> An acute phase occurs in the dermis with the releasing of many proinflammatory cytokines and mediators, with moderate collagen-fibre shrinkage and oedema. The damaged dermal tissue is massed in columns of debris, which move through the epidermis to the stratus corneum and then exfoliate. After this first phase there is a proliferative phase with the recruitment of fibroblasts and deposition of new type-III collagen fibres and dermal matrix; the last phase is characterized by collagen remodelling, when the thinner type-III collagen fibres are replaced by type-I collagen fibres.<sup>33–38</sup> The laser system (SmartXide<sup>2</sup> DOT/RF) we used in this study simultaneously delivers laser and bipolar radiofrequency; the latter is able to amplify and enhance the effects of the CO<sub>2</sub> laser by remodelling the tissue in-depth, toning flabbiness and stimulating fibroblast activity to produce new collagen.<sup>21–28</sup> Previous histological studies have in fact confirmed the presence of thickened, shortened collagen fibrils after bipolar radiofrequency treatments and an increased collagen-I upregulation has been observed through the northern blot analysis.<sup>26</sup> It has therefore been demonstrated how fractional CO<sub>2</sub> laser and radiofrequency are able to induce similar histological modifications in the superficial layers of the skin. The simultaneous emission of CO<sub>2</sub> fractional laser and radiofrequency currents yields several significant beneficial effects. In particular, there is a transfer of energy from the surface to the deeper layers with a more uniform lateral diffusion of the biostimulation (Fig. 10). The laser-radiofrequency combination minimizes the amount of energy required from each system to



**Figure 10** Synergy between CO<sub>2</sub> and bipolar RF current.



achieve the desired results, decreasing the possibilities of side-effects. The recovery times were between 3 and 7 days in nearly all patients, and the erythema usually never lasted longer than 7 days, showing a reduction in superficial hyperaemia. The average downtime for the fractional CO<sub>2</sub> laser/bipolar radiofrequency device in group B was 5.4 days, showing a slight reduction compared with previous results using fractional CO<sub>2</sub> laser alone.<sup>20–39</sup> Faster healing allowed patients to return to a normal life in public within the first week after the laser session, as there were no marked side-effects to hide or tolerate. Despite a few predictable side-effects like erythema and oedema, the majority of patients were very satisfied, which suggests that the low downtime and side-effects associated with the laser procedure were well tolerated thanks to the degree of improvement achieved at the end of the treatments. Moreover, our preliminary results with the CO<sub>2</sub> laser/bipolar radiofrequency device, compared with our previous experience with CO<sub>2</sub> laser,<sup>39</sup> showed that good patient satisfaction was achievable with fewer treatments; the average number of sessions for group A was 1.85 while for group B, it was 3.65.

## Conclusions

These skin tightening and rhytide reduction results can be achieved via the use of lower parameters, without the risk of side-effects from higher settings, thanks to the combined use of laser and bipolar radiofrequency. A remarkable advantage is the control of erythema, both in terms of absolute intensity and duration. These aspects are vitally important for reducing the period of 'social exclusion' imposed by the procedure. In conclusion, our findings from clinical evaluations and experimental investigations suggest that resurfacing using fractional CO<sub>2</sub> laser with new pulse shape emission integrated with bipolar radiofrequency is efficacious in improving the treatment of patients with various degrees of photodamage and also in reducing downtime. This kind of laser meets the needs of the majority of dermatologists, who require a unique, versatile tool to remove skin lesions and at the same time safely and effectively treat skin imperfections. This is now possible thanks to the promising clinical results obtained with an ablative laser like CO<sub>2</sub>, and the reduced risks of side-effects and shorter downtimes achieved when resurfacing with fractional CO<sub>2</sub> laser combined with bipolar radiofrequency.

## References

- Oni G, Mahaffey PJ. Treatment of recalcitrant warts with the carbon dioxide laser using an excision technique. *J Cosmet Laser Ther* 2011; **13**: 231–236.
- Pozo J, Castineiras I, Fernandez-Jorge B. Variants of milia successfully treated with CO<sub>2</sub> laser vaporization. *J Cosmet Laser Ther* 2010; **12**: 191–194.
- Madan V, Ferguson JE, August PJ. Carbon dioxide laser treatment of rhinophyma: a review of 124 patients. *Br J Dermatol* 2009; **161**: 814–881.
- Boyce S, Alster TS. CO<sub>2</sub> laser treatment of epidermal nevi: long-term success. *Dermatol Surg* 2002; **28**: 611–614.
- Cho SB, Kim HJ, Noh S, Lee SJ, Kim YK, Lee JH. Treatment of syringoma using an ablative 10,600-nm carbon dioxide fractional laser: a prospective analysis of 35 patients. *Dermatol Surg* 2011; **37**: 433–438.
- Raulin C, Schoenermark MP, Werner S, Greve B. Xanthelasma palpebrarum: treatment with the ultrapulsed CO<sub>2</sub> laser. *Lasers Surg Med* 1999; **24**: 122–127.
- Aynaud O, Buffet M, Roman P, Plantier F, Dupin N. Study of persistence and recurrence rates in 106 patients with condyloma and intraepithelial neoplasia after CO<sub>2</sub> laser treatment. *Eur J Dermatol* 2008; **18**: 153–158.
- Riggs K, Keller M, Humphreys TR. Ablative laser resurfacing: high-energy pulsed carbon dioxide and erbium:yttrium-aluminum-garnet. *Clin Dermatol* 2007; **25**: 462–473.
- Hunzeker CM, Weiss ET, Geronemus RG. Fractioned CO<sub>2</sub> laser resurfacing: our experience with more than 2000 treatments. *Aesthet Surg J* 2009; **29**: 317–822.
- Neaman KC, Baca ME, Piazza RC, VanderWoude DL, Renucci JD. Outcomes of fractional CO<sub>2</sub> laser application in aesthetic surgery: a retrospective review. *Aesthet Surg J* 2010; **30**: 845–852.
- Karsai S, Czarnecka A, Junger M, Raulin C. Ablative fractional lasers (CO<sub>2</sub> and Er:YAG): a randomized controlled double-blind split-face trial of the treatment of peri-orbital rhytides. *Lasers Surg Med* 2010; **42**: 160–167.
- Tierney EP, Hanke CW. Ablative fractionated CO<sub>2</sub> laser resurfacing for the neck: prospective study and review of the literature. *J Drugs Dermatol* 2009; **8**: 723–731.
- Gotkin RH, Sarnoff DS, Cannarozzo G, Sadick NS, Alexiades-Arménakas M. Ab lative skin resurfacing with a novel microablative CO<sub>2</sub> laser. *J Drugs Dermatol* 2009; **8**: 138–144.
- Manstein D, Herron GS, Sink RK, Tanner H, Anderson RR. Fractional photothermolysis: a new concept for cutaneous remodeling using microscopic patterns of thermal injury. *Lasers Surg Med* 2004; **34**: 426–438.
- Carniol PJ, Harirchian S, Kelly E. Fractional CO<sub>2</sub> laser resurfacing. *Facial Plast Surg Clin North Am* 2011; **19**: 247–251.
- Ciocon DH, Engelman DE, Hussain M, Goldberg DJ. A split-face comparison of two ablative fractional carbon dioxide lasers for the treatment of photodamaged facial skin. *Dermatol Surg* 2011; **37**: 784–790.
- Li YH, Chen JZ, Wei HC *et al*. A Chinese experience of fractional ultrapulsed CO<sub>2</sub> laser for skin rejuvenation. *J Cosmet Laser Ther* 2010; **12**: 250–255.
- Chan NP, Ho SG, Yeung CK, Shek SY, Chan HH. Fractional ablative carbon dioxide laser resurfacing for skin rejuvenation and acne scars in Asians. *Lasers Surg Med* 2010; **42**: 615–623.
- Omi T, Kawana S, Sato S, Bonan P, Naito Z. Fractional CO<sub>2</sub> laser for the treatment of acne scars. *J Cosmet Dermatol* 2011; **10**: 294–300.
- Bonan P, Campolmi P, Cannarozzo G *et al*. Eyelid skin tightening: a novel 'Niche' for fractional CO<sub>2</sub> rejuvenation. *J Eur Acad Dermatol Venereol* 2012; **26**: 186–193.
- Newman J. Radiofrequency(GFX) ablation for the reduction of glabellar frowning. *Facial Plast Surg* 2010; **26**: 266–273.
- Brightman L, Goldman MP, Taub AF. Subablative rejuvenation: experience with a new fractional radiofrequency system for skin rejuvenation and repair. *J Drugs Dermatol* 2009; **8**: S9–213.
- Paasch U, Bodendorf MO, Grunewald S, Simon JC. Skin rejuvenation by radiofrequency therapy: methods, effects, and risks. *J Dtsch Dermatol Ges* 2009; **7**: 196–203.
- Montesi G, Calvieri S, Balzani A, Gold MH. Bipolar radiofrequency in the treatment of dermatologic imperfections: clinicopathological and immunohistochemical aspects. *J Drugs Dermatol* 2007; **6**: 890–896.
- Sadick N. Bipolar radiofrequency for facial rejuvenation. *Facial Plast Surg Clin North Am* 2007; **15**: 161–167.
- Geraghty LN, Biesman BS. Wrinkles and acne scars: technology-based treatment of periorbital wrinkles. in: *Laser and IPL technology in*

- dermatology and aesthetic medicine* (Raulin C, Karsai S, eds) Springer-Verlag Berlin Heidelberg, Berlin, 2011; 299–305
- 27 Kim JE, Chang S, Won CH *et al.* Combination treatment using bipolar radiofrequency-based intense pulsed light, infrared light and diode laser enhanced clinical effectiveness and histological dermal remodeling in Asian photoaged skin. *Dermatol Surg* 2012; **38**: 68–76.
  - 28 Lee HS, Lee DH, Won CH *et al.* Fractional rejuvenation using a novel bipolar radiofrequency system in Asian skin. *Dermatol Surg* 2011; **37**: 1611–1619.
  - 29 Karsai S, Raulin C. Comparison of clinical outcome parameters, the Patient Benefit Index (PBI-k) and patient satisfaction after ablative fractional laser treatment of peri-orbital rhytides. *Lasers Surg Med* 2010; **42**: 215–223.
  - 30 Tenna S, Cogliandro A, Piombino L, Filoni A, Persichetti P. Combined use of fractional CO<sub>2</sub> laser and radiofrequency waves to treat acne scars: a pilot study on 15 patients. *J Cosmet Laser Ther* 2012; **14**: 166–171. Jun 1. In press.
  - 31 Hantash BM, Bedi VP, Chan KF, Zachary CB. *Ex vivo* histological characterization of a novel ablative fractional resurfacing device. *Lasers Surg Med* 2007; **39**: 87–95.
  - 32 Hantash BM, Bedi VP, Kapadia B *et al.* *In vivo* histological characterization of a novel ablative fractional resurfacing device. *Lasers Surg Med* 2007; **39**: 96–107.
  - 33 Prignano F, Bonciani D, Campolmi P, Cannarozzo G, Bonan P, Lotti T. A study of fractional CO<sub>2</sub> laser resurfacing: the best fluence through a clinical, histological, and ultrastructural evaluation. *J Cosmet Dermatol* 2011; **10**: 210–216.
  - 34 Reilly MJ, Cohen M, Hokugo A, Keller GS. Molecular effects of fractional carbon dioxide laser resurfacing on photodamaged human skin. *Arch Facial Plast Surg* 2010; **12**: 321–325.
  - 35 Trelles MA, Shohat M, Urdiales F. Safe and effective one-session fractional skin resurfacing using a carbon dioxide laser device in super-pulse mode: a clinical and histologic study. *Aesthetic Plast Surg* 2011; **35**: 31–42.
  - 36 Sasaki GH, Travis HM, Tucker B. Fractional CO<sub>2</sub> laser resurfacing of photoaged facial and non-facial skin: histologic and clinical results and side effects. *J Cosmet Laser Ther* 2009; **11**: 190–201.
  - 37 Prignano F, Campolmi P, Bonan P *et al.* Fractional CO<sub>2</sub> laser: a novel therapeutic device upon photobiomodulation of tissue remodelling and cytokine pathway of tissue repair. *Dermatol Ther* 2009; **22**(Suppl 1): s8–15.
  - 38 Saluja R, Khoury J, Detwiler SP, Goldman MP. Histologic and clinical response to varying density settings with a fractionally scanned carbon dioxide laser. *J Drugs Dermatol* 2009; **8**: 17–20.
  - 39 Campolmi P, Bonan P, Cannarozzo G *et al.* Highlights of thirty-year experience of CO<sub>2</sub> laser use at the Florence (Italy) department of dermatology. *Sci World J* 2012. Epub 2012 Apr 19.