

Original Articles

Authors:

Natacha Quezada Gaón¹
Fernanda Binfa²

¹ Dermatologist physician, Post-graduate degree in dermatocosmiatrics from the Faculdade de Medicina ABC (FMABC) São Paulo (SP), Brazil. Coordinator, Dermatoacosiatria Department, Dermatology Service, Medical School, PUC-Chile Santiago, Chile.

² Medical surgeon from the Facultad de Medicina da Universidad Católica de la Santísima Concepción (UCSC) – Concepción, Chile.

Correspondence:

Natacha Quezada Gaón
Hospital Clínico Pontificia
Universidad Católica de Chile
Marcoleta 350, 2º andar
Santiago Región Metropolitana - Chile
E-mail: natachaq@yahoo.es

Received on: 16/12/2016

Approved on: 12/03/2017

This study was carried out at the Dermatology Service of the Pontificia Universidad Católica de Chile (UC) - Santiago, Chile.

Financial support: none

Conflict of interests: none

The effect of intraoral 2,940nm non-ablative Erbium:YAG laser on the rejuvenation of the upper lip: a pilot study

Efeito do laser não ablativo Erbium YAG 2940nm intraoral no rejuvenescimento do lábio superior: estudo-piloto

DOI: <http://dx.doi.org/10.5935/scd1984-8773.201791953>

ABSTRACT

Introduction: Increased distance between the base of the nose and lip's vermilion is difficult to treat, and often there are restrictions for the use of botulinum toxin and cutaneous fillers.

Objective: To describe a new technique for the treatment of the upper lip ptosis.

Methods: A prospective pilot study was conducted with 15 female patients bearing increased distance between the base of the nose and the labial cutaneous-mucosal transition line. Five weekly sessions of intraoral non-ablative 2,940nm Er:YAG laser were performed. For the evaluation of outcomes, standardized records were performed with a 3D photographic camera, and comparative measurements of the philtrum's height and the nasolabial angle were taken before and after the treatment.

Results: There was a shortening ranging from 2 to 4 mm in the philtrum's measurements, and a decrease in the nasolabial angle, in addition to increased firmness of the skin in the upper lip.

Conclusion: Intraoral non-ablative 2,940nm Er:YAG laser can be a therapeutic option for the treatment of upper lip ptosis.

Keywords: Aging; Lasers; Lip

RESUMO

Introdução: O aumento da distância entre a base do nariz e o vermelhão do lábio é de difícil tratamento, e muitas vezes apresenta limites para o uso de toxina botulínica e preenchedores.

Objetivo: Descrever nova técnica para o tratamento da ptose do lábio superior.

Métodos: Realizado estudo-piloto prospectivo com 15 pacientes do sexo feminino que apresentavam aumento da distância entre a base do nariz e a linha de transição cutâneo-mucosa labial. Foram realizadas cinco sessões semanais de laser não ablativo Er:YAG 2940nm intraoral. Para a avaliação dos resultados, foram feitos registro padronizado com câmera fotográfica de 3D e medidas comparativas da altura do filtro e do ângulo subnasal, antes e após o tratamento.

Resultado: Observou-se encurtamento que variou de dois a 4mm nas medidas do filtro, e diminuição do ângulo subnasal, além de maior firmeza da pele do lábio superior.

Conclusão: O laser não ablativo Er:YAG 2940nm intraoral pode ser opção terapêutica para a ptose do lábio superior.

Palavras-chave: Rejuvenescimento; Lasers; Lábio

INTRODUCTION

The increase in the distance between the base of the nose and the cutaneous-mucosal line of the lips, resulting from sagging skin, which loses turgor and elasticity, is an important characteristic in the natural process of chronological aging and photoaging processes of the lower third of the face. In young people, the upper lip presents a slight convexity in the region of the cupid's bow and the philtrum, however there is flattening and elongation in this region over time. Also, the vermilion of the lips is characteristically turgid in young people; nevertheless

its thickness decreases with the aging process, and perioral wrinkles emerge at the same time (Figure 1).

Although botulinum toxin and hyaluronic acid are of great help in facial rejuvenation, the increase in the height of the upper lip's cutaneous portion limits its use in minimally invasive procedures.¹ In this manner, in order to treat this condition, it is necessary to resort to surgical techniques, which not all patients are willing to undergo.²⁻⁴

Non-ablative Er:YAG laser is a relatively new technology. This 2,940nm laser exerts a thermal effect that remodels the collagen and also stimulates the induction of neocollagenesis when applied to the oral mucosa set at the *smooth* mode. Among the few existing publications on this technology, some address the reduction of the nasogenian fold and perioral wrinkles.⁵⁻⁸

METHODS

A prospective pilot study was conducted with 15 volunteer women aged 45 to 72 years, and II to IV Fitzpatrick phototypes, originary from Santiago, Chile. The patients were submitted to five weekly sessions of intraoral non-ablative 2,940nm Er:YAG laser (Dynamis® SP, Fotona, Ljubljana, Slovenia) set at the *smooth* mode, with the following parameters: 9J/cm², 1.8Hz, Spot 7mm. The shots were geometrically delivered in four rows and were performed only in the inner region of the labial mucosa. The exclusion criterion was trauma and active bacterial or viral infections in the treatment area. The study complied with the Helsinki Declaration.

The evaluations were performed based on standardized photographs taken with the Vectra H1® camera (Canfield, NJ, USA), which generates 3D images and measurements of the length of the philtrum and nasolabial angle, before and after the five weekly laser sessions, aimed at providing a quantitative measurement of the results (Figure 2).

RESULTS

Based on the quantitative evaluation of the philtrum's distance, it was possible to conclude that 60% of patients experienced a 4mm decrease in the philtrum's length, while 30% of them had a 3mm decrease, and 20% had a 2mm decrease (Figure 3).

Analyzing the standardized photographs with the Vectra H1 camera, it was possible to observe an improvement in

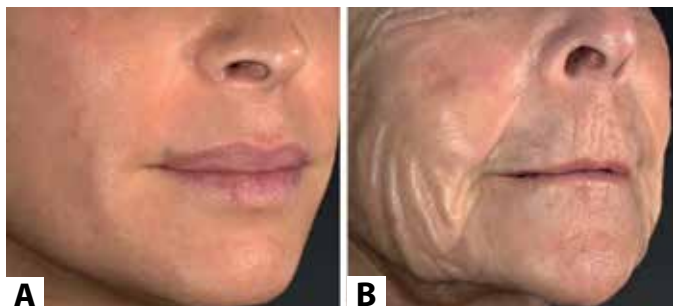

FIGURE 1: Perioral Aging - A: Young lips; B: Aged lips

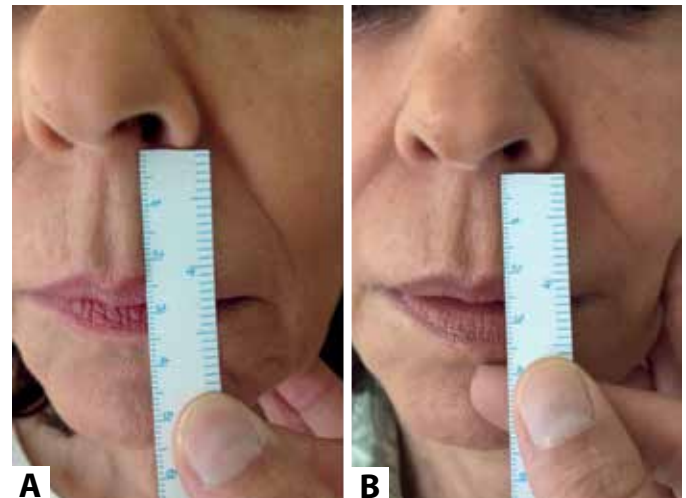


FIGURE 2: Measurement of the philtrum's length
A: Before; B: After five non-ablative intraoral Er:YAG laser sessions

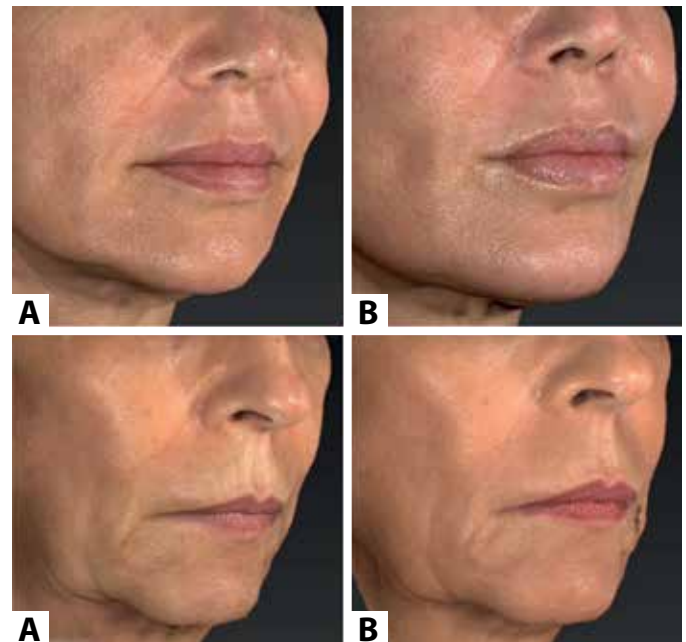

FIGURE 3: A - Before; B - After five laser sessions

the projection of the upper lip: 40% of the cases had a 5° decrease in the nasolabial angle, while 60% of cases experienced a 3° decrease.

As a consequence, there was a slight increase of the prominence of the cupid's bow and a slight eversion of the vermillion in all cases (Figure 4).

DISCUSSION

In the global approach to rejuvenation with minimally invasive procedures, increasing the distance between the base of the nose and the lip's cutaneous-mucosal transition is a proposition that has few therapeutic alternatives.

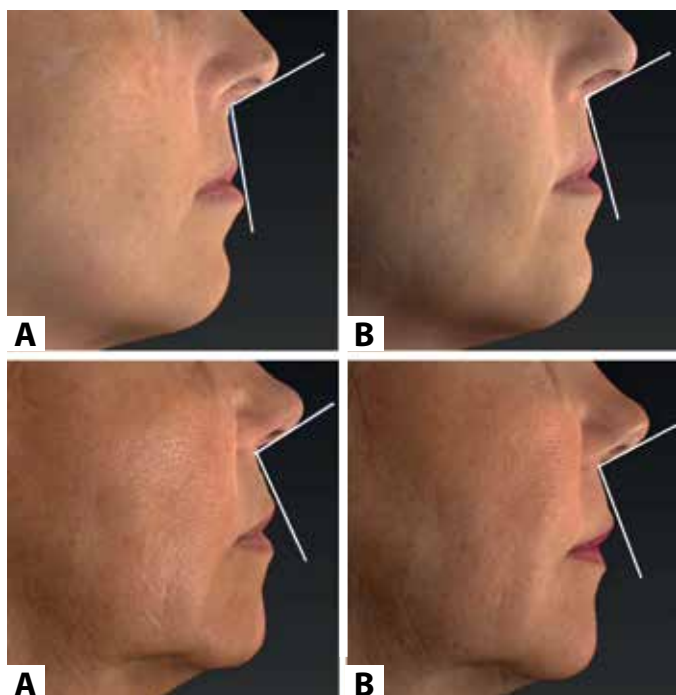


FIGURE 4: Modification of the subnasal angle - **A:** Before, **B:** After five laser sessions

The injection of botulinum toxin in the orbicularis muscle of the lips can be used with the purpose of inducing eversion of the vermillion, however its use is limited by the limited num-

ber of units that can be applied in this region due to the risk of the impact it might have on the harmony of the facial mimicry of the lower third and on the chewing process.

As a matter of fact, although widely used in the perioral region, hyaluronic acid based cutaneous fillings produce a highly unsightly effect that go against the rules of facial proportionality 3 in case the vermillion's volume is increased to compensate for the vertical elongation of the cutaneous portion of the upper lip.

The literature cites surgical techniques that can be used to correct ptosis in the upper lip, 2-4 however many patients prefer less invasive procedures that offer no possibility of scars.

After five non-ablative 2,940nm Er:YAG laser intraoral treatment sessions carried out in this pilot study, it was possible to demonstrate the presence of a decrease in the philtrum's length and vermillion eversion.

In 2013, Gaspar & Gasti successfully used this same method for the treatment of nasolabial folds and perioral rhytids. Just as in the present study, it yielded good results and no patient discomfort or complications were reported.

In this manner, the described alternative procedure leads to moderate results, however there is absence of ablation, recovery period and complications.

CONCLUSION

Intraoral non-ablative Er:YAG laser improves sagging and shortens the upper lip after several sessions, meaning that this technique is an interesting tool in the treatment of perioral rejuvenation. ●

REFERENCES

1. Braz A, Humphrey S, Weinkle S, Yee GJ, Remington BK, Lorenc ZP, et al. Lower Face: clinical anatomy and regional approaches with injectable fillers. *Plast Reconstr Surg*. 2015;136(5 Suppl):235S-257S.
2. Raphael P, Harris R, Harris SW. The Endonasal Lip Lift: Personal Technique. *Aesthet Surg J*. 2014;34(3):457-468.
3. Paixão MP, Montedonio J, Queiroz-Filho W, Pouza CET, Almeida AEF. Lifting de lábio superior associado à dermoabrasão mecânica. *Surg Cosmet Dermatol*. 2011;3(3):249-53
4. Suzuki HS, Seidel GB, Soares VC, Hepp T, Helmer K. Tratamento cirúrgico da inversão labial do envelhecimento. *Surg Cosmet Dermatol*. 2014;6(3):282-3.
5. Drnovsek-Olup B, Beltram M, Pizem J. Repetitive Er:YAG laser irradiation of human skin: a histological evaluation. *Lasers Surg Med*. 2004;35(2):146-51.
6. Drnovsek-Olup B, Beltram M, Pizem J. Repetitive Er:YAG laser irradiation of human skin: a histological evaluation. *Lasers Surg Med*. 2004;35(2):146-151.
7. Volkova NV, Glazkova LK, Khomchenko VV, Sadick NS. Novel method for facial rejuvenation using Er:YAG laser equipped with a spatially modulated ablation module: An open prospective uncontrolled cohort study. *J Cosmet Laser Ther*. 2016;19(1):25-29.
8. Gaspar A, Gasti GA. Tightening of Facial Skin Usin Intraoral 2940 nm Er:YAG SMOOTH Mode. *Journal of the Laser and Health Academy*. 2013;2:17-20
9. Carruthers J, Carruthers A. Aesthetic botulinum A toxin in the mid and lower face and neck. *Dermatol Surg*. 2003;29(5):468-76.