

CASE REPORT: Treatment of Acne Vulgaris with Long-Pulsed 1064 nm Nd:YAG Laser

Robin Sult

Aesthetics, Inc, Willmar, MN 56201, USA

ABSTRACT

Acne vulgaris, clinically classified as inflammatory or non-inflammatory acne, is a chronic skin disease of pilosebaceous units with multifactorial pathogenesis. Although most prevalent among adolescents, acne can also be present in children and adults. Due to the large impact on quality of life, there is a great need for effective and safe treatment of acne. Recently several reports have described using light sources, including lasers, as an alternative treatment.

To evaluate the effectiveness of long-pulsed 1064 nm Nd:YAG laser for acne treatment, we reported four cases of successful acne treatment of different types.

The treatment was well tolerated by the patient with mild pain described during the treatment. There was no anesthesia or cold air needed to reduce the pain. No reoccurrence of acne was observed. An additional advantage of 1064 nm Nd:YAG acne treatment is its potential to improve acne scars.

We can conclude that acne treatment with 1064 nm Nd:YAG is a safe, effective and well-tolerated treatment with long-term results and no side effects reported.

Article: J. LA&HA, Vol. 2014, No.1; pp.57-60.

Received: April 15, 2014; Accepted: April 22, 2014

© Laser and Health Academy. All rights reserved.

Printed in Europe. www.laserandhealth.com

I. INTRODUCTION

Acne vulgaris is one of the most common chronic skin diseases of pilosebaceous units with multifactorial pathogenesis. Acne development is commonly associated with excessive follicular keratinization, leading to follicular plugs (comedones), androgen related hyperplasia of the sebaceous glands and increased sebum, colonization with *Propionibacterium acnes* and inflammatory response. Clinically it can be classified as inflammatory and non-inflammatory acne. In non-inflammatory acne, comedones can be observed, while inflammatory acne is associated with papules, pustules and nodulocystic lesions causing

atrophic or hypertrophic scars [1,2]. The most affected areas with the greatest number of sebaceous glands are the face, neck and upper torso.

Acne is most prevalent among adolescents and young adults, affecting approximately 80% of people between 11–30 years of age, however it is also present in children and adults [3,4].

Due to the large impact on quality of life, acne is no longer regarded simply as a physiological condition or a cosmetic problem. There is a great need for safe and effective treatments of acne. Large numbers of local and systemic therapies are available for acne treatments. Common oral or topical retinoids, antibiotics or keratolytics are used but are inconvenient, and side effects caused by these conventional therapies prompted a search for more acceptable treatments.

An increase in research regarding effective acne treatments with different light sources, including laser source treatment, has been detected recently [5,6]. Although, there are numerous studies describing the efficacy of 1064 nm Nd:YAG lasers for the treatment of acne scars [7–9], there is little known about their efficacy against acne infection treatment [10–12].

In this paper, four cases of successful treatment of acne vulgaris with long-pulsed 1064 nm Nd:YAG laser have been reported.

II. CASES

a) Case 1

A young female patient, age 17, presented with mild acne vulgaris and multiple inflammatory papules on the forehead, as seen in Fig. 1A.

A single treatment with Nd:YAG laser (XP Max, Fotona) was performed at Laser Aesthetics Clinic in Willmar, USA. A scanner with 6.0 mm spot size was used with fluence set at 50 J/cm², 14 ms pulse duration and frequency 1.5 Hz. Eye protection was provided by using stainless steel scleral shields. No anesthesia or cold air cooling was needed.

Significant reduction of acne was observed after only one treatment with Nd:YAG laser (Fig. 1B). The maintenance of acne reduction was monitored and there was no sign of recurrence of acne even 5 years after the treatment. No side effect was noticed immediately or later after the treatment.

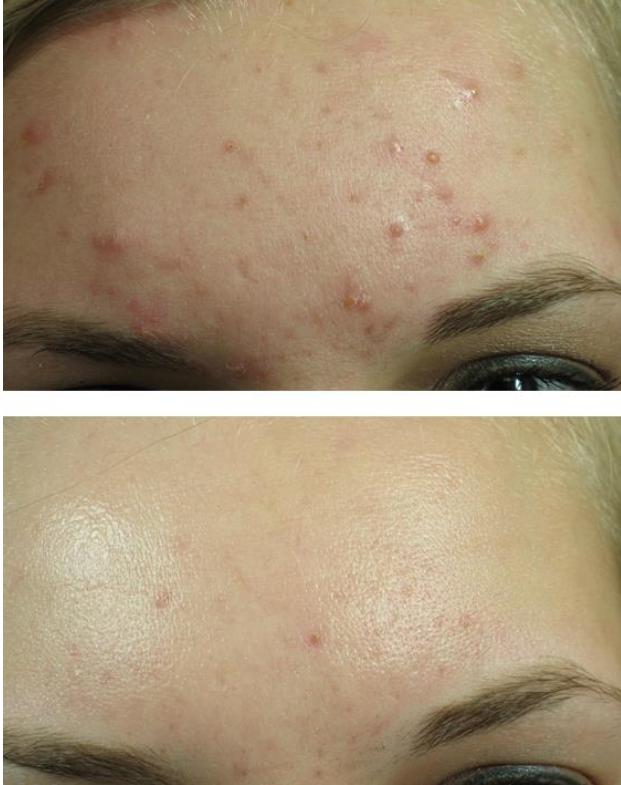

Figure 1: a) Mild acne vulgaris with multiple inflammatory papules on the forehead before the treatment with 1064 nm Nd:YAG laser. b) After only one session significant reduction of acne was detected.

b) Case 2

A teenage female patient, age 15, with several years of unsuccessfully treated moderate acne came to Laser Aesthetics Clinic in Willmar, USA. Before treatment with Nd:YAG laser (XP Max, Fotona), the patient changed 3 different physicians and 7 different prescriptive medications with no significant results noticed. A few papules and pustules were observed on the cheeks (Fig. 2A) on the first visit at the clinic.

The patient was treated with Nd:YAG laser (XP Max, Fotona) with 6.0 mm spot size and parameters set at 50 J/cm² fluence, pulse duration 14 ms and frequency 1.5 Hz. Eye protection was provided by using stainless steel scleral shields. No anesthesia or cold air cooling was needed.

With a single treatment, complete clearance with no side effects was achieved (Fig. 2B). No reoccurrence was reported 10 years after the treatment.

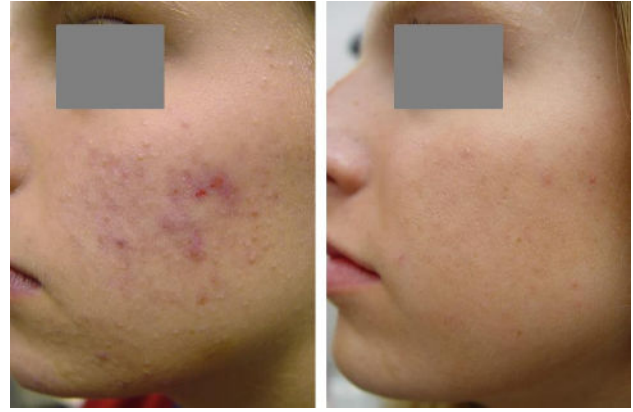

Figure 2: a) Acne vulgaris with papules and pustules on cheeks after several years of unsuccessful treatment with medications (before 1064 nm Nd:YAG treatment). b) Complete clearance observed after a single laser treatment.

c) Case 3

A male patient, age 23, with Fitzpatrick IV-V skin type was guided to the Laser Aesthetics Clinic in Willmar, USA with mild acne vulgaris visible on the cheeks and neck (Fig. 3A).

A single-session Nd:YAG laser (XP Max, Fotona) treatment with settings of 6 mm spot size (S11 Scanner), 40 J/cm² fluence, 14 ms pulsewidth and 1.5 Hz frequency was needed to completely clear papules as seen in Fig. 3B. No topical anesthesia, or cooling, was used before or during the treatment.

Complete clearance was observed. A 5-year follow up was conducted with no reoccurrence detected.

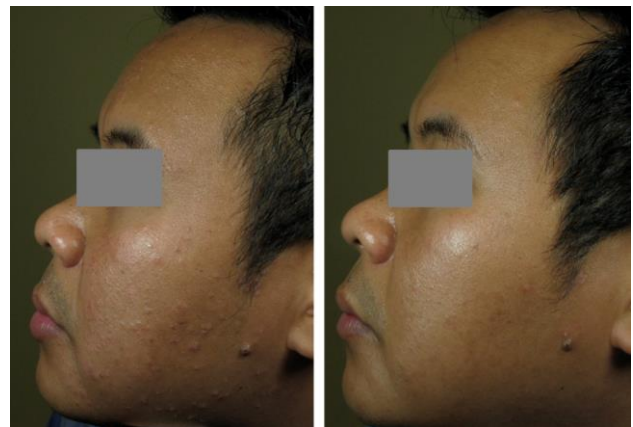


Figure 3: a) Mild acne vulgaris visible on cheeks and neck before long-pulsed 1064 nm Nd:YAG therapy. b) Complete clearance after a single treatment with Nd:YAG.

d) Case 4

A young male patient, age 18, with moderate inflammatory acne as well as acne scars visible on the cheek and chin, was treated in Laser Aesthetics Clinic with Nd:YAG laser (XP Max, Fotona).

A single treatment with 6.0 mm spot size, fluence set at 50 J/cm², 14 ms pulse duration and 1.5 Hz frequency was used. Stainless steel scleral shields were used to protect the eyes from laser irradiation. Treatment was well tolerated by the patient and there was no anesthesia or cold air cooling needed.

Significant clearance of acne as well as acne scar improvement with no side effect was observed after the laser treatment.

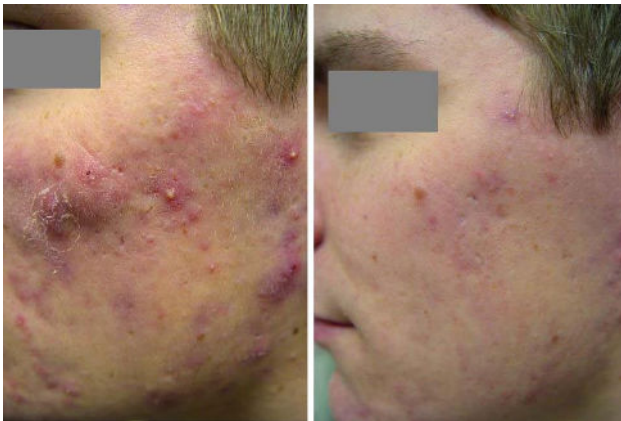

Figure 4: a) Moderate inflammatory acne as well as acne scars visible on the cheeks and chin before 1064 nm Nd:YAG laser treatment. b) After only one treatment session significant reduction of acne vulgaris was observed.

III. DISCUSSION

Laser therapies using various wavelengths were considered in response to a need of alternative treatment options. The laser treatments are based on two mechanisms of action. Medical devices with blue to red light as well as intensive pulsed light (IPL) destroy *Propionibacterium acnes* by absorption of endogenous porphyrins produced by *P.acnes* resulting in a cytotoxic effect on the bacteria [13–15]. Since these therapies do not target the sebaceous gland, there is a high risk of recurrence due to repopulation by *P.acnes*. On the other hand, treatments with lasers in the near infrared spectrum of light are based on thermally damaging the sebaceous glands. Several near infrared lasers such as 1320 nm, 1450 nm as well as 1540 nm lasers have been studied for acne vulgaris treatment [16–20]. An additional advantage of using infrared lasers for acne treatment is their potential to improve scars developed as a result of inflammatory acne vulgaris [9,21,22].

While there are numerous studies indicating the effective use of 1064 nm Nd:YAG lasers for the acne scar treatment [7–9], there is very little known about efficacy against acne infection. Case reports by Ballin and Winstanley reported an improvement of acne vulgaris with low level 1064 nm Nd:YAG [10,11].

Another study performed by Chun et al. reported improvement of severe pustular and cystic acne using combination of topical carbon lotion and Q-switched 1064 nm Nd:YAG treatment [12].

The great potential of long-pulsed 1064 nm Nd:YAG laser light is derived from its capability to penetrate deep into the skin to thermally and selectively destroy overactive sebaceous glands [23] and reduce acne inflammation. In addition to its thermal penetration effects, the 1064 nm Nd:YAG also accelerates the healing process and stimulates collagen remodeling, an important step in the long-term treatment of acne. There are also a few reports about long-pulsed 1,064-nm Nd:YAG laser increasing the dermal collagen in association with the increased expression of transforming growth factor beta TGF- β [24,25].

In our case report study, we demonstrated the use of long-pulsed 1064 nm Nd:YAG in the successful treatment of acne vulgaris. Four patients with different types of acne vulgaris were treated. A single session was sufficient to treat mild to moderate acne vulgaris. In Case 4 the reduction of acne scars was also observed (Fig 4b), which represents additional advantage of this treatment. All patients have tolerated the treatments well, with only mild pain described during the treatment, so there was no anesthesia or cold air needed for pain reduction. Except for mild erythema, detected immediately post-treatment and disappeared within one day, there were no adverse effects observed. This is also the first study describing long-term improvement of acne vulgaris with 1064 nm Nd:YAG laser. In a few years follow-up, no reoccurrence of acne was reported.

Based on the four cases described in this study, we can conclude that acne treatment with long-pulsed 1064 nm Nd:YAG is a safe, effective and well-tolerated treatment with long-term results and no side effects reported.

REFERENCES

1. Plewig G KA (2000) Acne and Rosacea. 3rd ed. New York: Springer-Verlag.
2. Gollnick HP, Zouboulis CC, Akamatsu H, Kurokawa I, Schulte A (1991) Pathogenesis and pathogenesis related treatment of acne. The Journal of dermatology 18: 489–499.
3. Cordain L (2002) Acne Vulgaris_{title>A Disease of Western Civilization}. Archives of Dermatology 138: 1584.
4. Goulden V, Stables GI, Cunliffe WJ (1999) Prevalence of facial acne in adults. Journal of the American Academy of Dermatology 41: 577–580.
5. Gold MH (n.d.) Efficacy of lasers and PDT for the treatment of acne vulgaris. Skin therapy letter 12: 1–6, 9.
6. Hamilton FL, Car J, Lyons C, Car M, Layton A, et al. (2009) Laser and other light therapies for the treatment of acne vulgaris: systematic review. The British journal of dermatology 160: 1273–1285.

7. Lee DH, Choi YS, Min SU, Yoon MY, Suh DH (2009) Comparison of a 585-nm pulsed dye laser and a 1064-nm Nd:YAG laser for the treatment of acne scars: A randomized split-face clinical study. *Journal of the American Academy of Dermatology* 60: 801–807.
8. Keller R, Belda Júnior W, Valente NY RC (2007) Nonablative 1,064-nm Nd:YAG Laser for Treating Atrophic Facial Acne Scars: Histologic and Clinical Analysis. *Dermatologic Surgery*:
9. Min SU, Choi YS, Lee DH, Yoon MY, Suh DH (2009) Comparison of a Long-Pulse Nd:YAG Laser and a Combined 585/1,064-nm Laser for the Treatment of Acne Scars: A Randomized Split-Face Clinical Study. *Dermatologic Surgery* 35: 1720–1727.
10. Ballin JS, Uebelhoefer NS (2009) The use of the low-fluence 1064 nm Nd:YAG laser in a female with contraindications to systemic anti-acne therapy. *Journal of drugs in dermatology: JDD* 8: 1025–1026.
11. Winstanley DA, Uebelhoefer NS (2008) Future considerations in cutaneous photomedicine. *Seminars in cutaneous medicine and surgery* 27: 301–308.
12. Chun S II, Calderhead RG (2011) Carbon assisted Q-switched Nd:YAG laser treatment with two different sets of pulse width parameters offers a useful treatment modality for severe inflammatory acne: a case report. *Photomedicine and laser surgery* 29: 131–135.
13. Meffert H, Gaunitz K, Gutewort T AU (1990) Therapy of acne with visible light. Decreased irradiation time by using a blue-light high-energy lamp. *Dermatologische Monatschrift* 176: 597–603.
14. Sigurdsson V, Knulst AC, Van Weelden H (1997) Phototherapy of Acne Vulgaris with Visible Light. *Dermatology* 194: 256–260..
15. Papageorgiou P, Katsambas A, Chu A (2000) Phototherapy with blue (415 nm) and red (660 nm) light in the treatment of acne vulgaris. *British Journal of Dermatology* 142: 973–978.
16. Lloyd JR, Mirkov M (2002) Selective photothermolysis of the sebaceous glands for acne treatment. *Lasers in Surgery and Medicine* 31: 115–120.
17. Paithankar DY, Ross EV, Saleh BA, Blair MA, Graham BS (2002) Acne treatment with a 1,450 nm wavelength laser and cryogen spray cooling. *Lasers in surgery and medicine* 31: 106–114.
18. Jih MH, Friedman PM, Goldberg LH, Robles M, Glaich AS, et al. (2006) The 1450-nm diode laser for facial inflammatory acne vulgaris: Dose-response and 12-month follow-up study. *Journal of the American Academy of Dermatology* 55: 80–87.
19. Bogle MA, Dover JS, Arndt KA MS (2007) Evaluation of the 1,540-nm Erbium:Glass Laser in the Treatment of Inflammatory Facial Acne. *Dermatologic Surgery* 33: 810–817.
20. Orringer JS, Kang S, Maier L, Johnson TM, Sachs DL, et al. (2007) A randomized, controlled, split-face clinical trial of 1320-nm Nd:YAG laser therapy in the treatment of acne vulgaris. *Journal of the American Academy of Dermatology* 56: 432–438.
21. Isarría MJ, Cornejo P, Muñoz E, Royo de la Torre J MJ (2011) Evaluation of clinical improvement in acne scars and active acne in patients treated with the 1540-nm non-ablative fractional laser. *J Drugs Dermatol* 10: 907–912.
22. Wada T, Kawada A, Hirao A, Sasaya H, Oiso N (2012) Efficacy and Safety of a Low-Energy Double-Pass 1450-nm Diode Laser for the Treatment of Acne Scars. *Photomedicine and Laser Surgery* 30: 107–111.
23. Bencini PL, Luci A, Galimberti M, Ferranti G (1999) Long-term epilation with long-pulsed neodymium:YAG laser. *Dermatologic surgery: official publication for American Society for Dermatologic Surgery* [et al] 25: 175–178.
24. Lee YB, Kang NH, Eun YS, Cheon MS, Kim KM, et al. (2012) Effects of long-pulsed 1,064-nm neodymium-doped yttrium aluminum garnet laser on dermal collagen remodeling in hairless mice. *Dermatologic surgery: official publication for American Society for Dermatologic Surgery* [et al] 38: 985–992.
25. Dang Y, Ye X, Weng Y, Tong Z, Ren Q (2010) Effects of the 532-nm and 1,064-nm Q-switched Nd:YAG lasers on collagen turnover of cultured human skin fibroblasts: a comparative study. *Lasers in medical science* 25: 719–726.

The intent of this Laser and Health Academy publication is to facilitate an exchange of information on the views, research results, and clinical experiences within the medical laser community. The contents of this publication are the sole responsibility of the authors and may not in any circumstances be regarded as official product information by medical equipment manufacturers. When in doubt, please check with the manufacturers about whether a specific product or application has been approved or cleared to be marketed and sold in your country.