

## REVIEW

# The TwinLight™ Concept in Dentistry

Ilay Maden, Ozge Erbil Maden, Zafer Kazak

Medicadent Oral and Dental Health Polyclinic, Muburdar Caddesi No. 69, Kadikoy, Istanbul, Turkey

### ABSTRACT

Lasers are used both as assistive as well as completely independent evidence-based tools in practically every field of dentistry, especially in terms of a multi-wave concept. Each type of laser has a different wavelength, and each wavelength has a unique interaction with a specific body tissue that is being treated [1], with the main effects varying from ablation to decontamination and photobiomodulation. From following any of the available dental laser curricula, it becomes clear that the optimal result of a particular dental laser therapy is achieved when two wavelengths are included in the treatment protocol. In the text that follows, the most widely used applications of the TwinLight™ treatment concept in dentistry are reviewed.

**Key words:** Er:YAG; Nd:YAG, TwinLight™

*Article: J. LA&HA, Vol. 2013, No. 1; pp. 11-16.*

*Received: April 24, 2013; Accepted: May 6, 2013.*

© Laser and Health Academy. All rights reserved.

Printed in Europe. www.laserandhealth.com

### LASER-ASSISTED SURGERY

A wide range of indications in oral surgery can be successfully treated by laser. The Er:YAG laser with variable pulse duration is a gold standard, because soft and hard tissues can be treated without any classical thermal or mechanical trauma, followed by excellent tissue healing. The Nd:YAG laser completes the success of TwinLight oral surgery treatments (Figure 1), as it is a perfect tool for the treatment of vascular lesions [2], for deep decontamination [3] and treatment of herpes and aphthae [4].

The absence of vibrations, faster healing of soft and bone tissues and relatively pain-free recovery, in addition to bactericidal and biostimulatory effects, make the Er:YAG laser an important surgical instrument. In special situations, such as the treatment of osteonecrosis of the jaws in patients under bisphosphonate therapy, these features become even more important [5]. Treatment success is completed with the LLLT step, provided by the Nd:YAG laser.

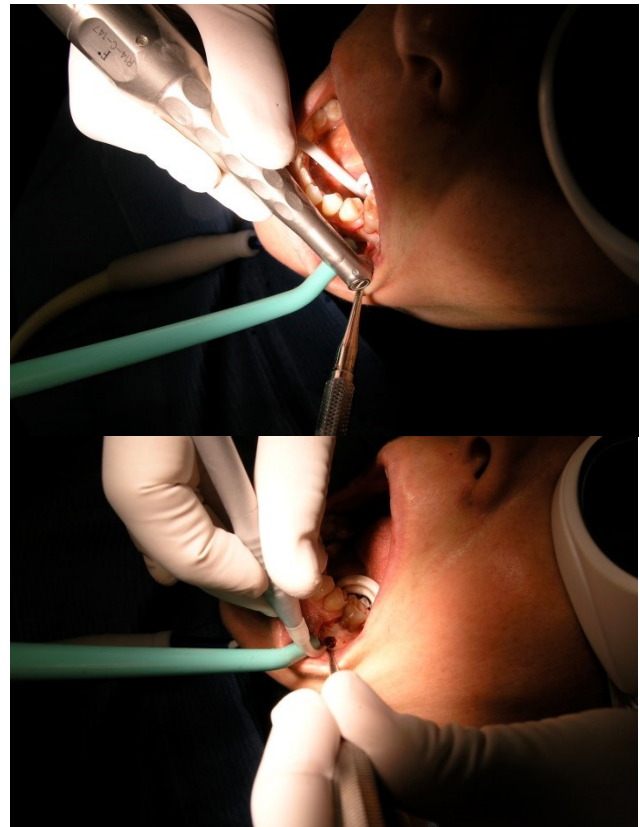

Fig. 1: Buccal opening, root resection and surface modification of the peri-apical lesion on the lower left first molar with the Er:YAG laser (a). Decontamination with the Nd:YAG laser (b). With permission of Dr. Kresimir Simunovic.

### LASER-ASSISTED ENDODONTICS

In root canal treatments the laser should be involved in two critical steps needed for successful treatment: for cleaning the smear layer in the root canal and for removing bacteria from all parts of the root canal system [6]. Classically, the complete removal of the smear layer is impossible, especially from the side canals. The Er:YAG laser wavelength is used for non-thermal, photoacoustic cleaning and debridement of the complex root-canal system. A saline solution or 17% EDTA and a specially shaped Er:YAG fiber tip are used for the effect of laser-induced photoacoustics. A combination of 6% sodium hypochlorite with an Er:YAG fiber tip effectively eliminates bacteria from the root canal [7,8]. As an

alternative to sodium hypochlorite, after the root canal is rinsed and dried, the Nd:YAG laser can be used for deep decontamination. With the TwinLight procedure (Figure 2), an effective success rate for endodontic cases is expected [9].

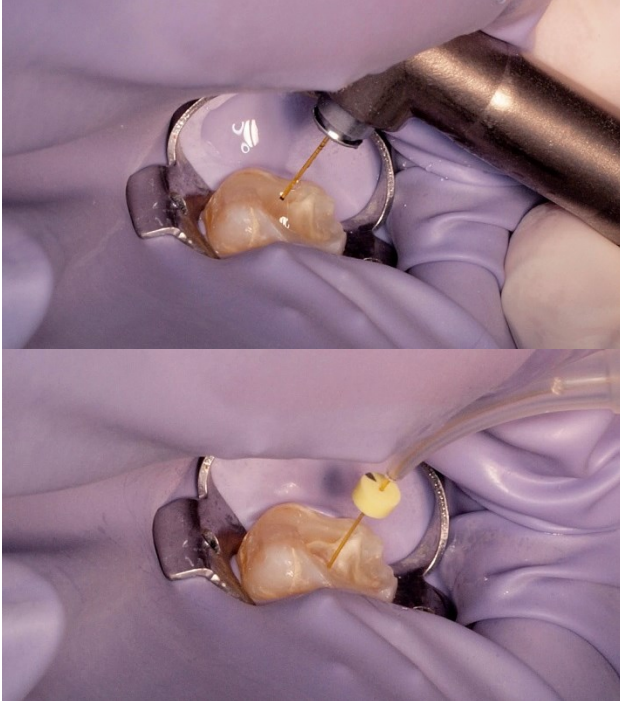


Fig. 2: Photoacoustic cleaning and debridement with Er:YAG (a). Dry and deep decontamination using Nd:YAG laser (b). With permission of Dr. Kresimir Simunovic.

### LASER-ASSISTED PERIODONTICS

Modern periodontal therapy deals with effective removal of infected soft and hard tissue during surgical or non-surgical therapy. There are various benefits of the combined use of laser-assisted and classical methods of periodontal treatments. The Er:YAG laser with an appropriate fiber tip is used for concrement and calculus ablation [10] while removing bacteria [11,12], endotoxins [13] and lipopolysaccharide on the hard root surface, and the elimination of granulomatous tissue on the soft gingival side. The Nd:YAG laser is an indispensable tool to initially decontaminate the pocket [14-17], as well as to deepithelise. Laser-assisted treatment provides successful clinical and microbial results as they are the best solution for decontamination and smear layer removal; eliminating the cause of the periodontal problem and providing a better surface for fibroblast attachment [18]. Both wavelengths help to improve the treatment outcomes [19-23] and patient comfort [21,24-26]. The TwinLight combination of Er:YAG and Nd:YAG laser-assisted, minimally invasive periodontal treatment (Figure 3) is able to replace classical invasive surgery or ease the procedure with increased access, selective removal of tissues and biomodulation during the surgical approach.

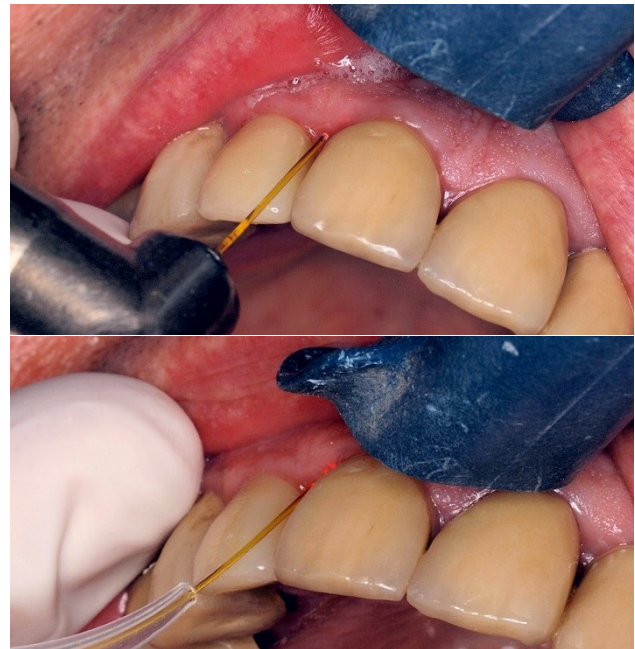

Fig 3: Laser assisted closed perio debridement: initial superficial decontamination and ablation of granulomatous tissue with Er:YAG (a). Deep decontamination and biomodulation with the Nd:YAG laser (b). With permission of Dr. Kresimir Simunovic.

Many perio-surgical procedures like gingivectomy, gingivoplasty, or operculectomy can be performed by lasers [27] in an elegant way. Very clean cuts of gingival tissue with a desired coagulation depth can be performed with a VSP (Variable Square Pulse Technology) Er:YAG laser without detrimental thermal effects. The surgery can also be combined with the TwinLight Nd:YAG step, if stronger hemostasis is required.

### LASER-ASSISTED ORAL IMPLANTOLOGY

In modern implant dentistry there are several clinical indications for laser surgery [28]. Different laser wavelengths are included in practically every step of the implant procedure.

The soft tissues that will surround the implant should be prepared before starting implant surgery. A number of laser wavelengths could be used for this step, but Er:YAG lasers cause less pain as they do not heat the tissue surface as do diode, Nd:YAG or CO<sub>2</sub> lasers, and the patient heals faster for the same reason [29].

The removal of granulation tissues and disinfection of the surgical area after extractions is the next important step in implant procedures where Er:YAG lasers have a crucial role (Figure 4). Because of the strong absorption of the Er:YAG laser beam in water, only soft tissue is removed if the parameters are adjusted correctly (energy density and pulse duration).



After the removal of granulation tissues and superficial disinfection [27], the Nd:YAG laser is used for deep disinfection and a biomodulation effect that helps with healing, leading to less edema and pain.

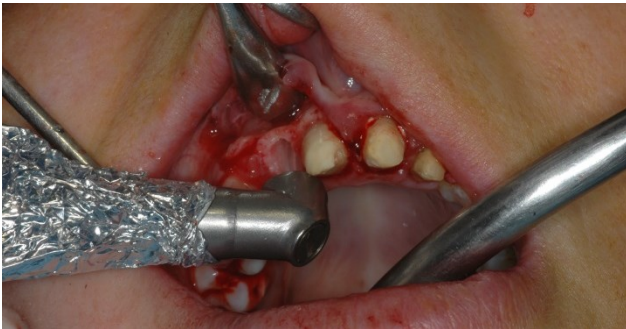

Fig. 4: Cleaning and disinfecting the socket with an Er:YAG laser after extraction.

Ablating the bone with Er:YAG [30] laser in order to have the desired coronal bone thickness, such as by removing a knife-edge thin portion to shape a plateau, or an osteotomy for sinus lift, or obtaining a bone block, or bone splitting is advantageous. Also, marking the location of the first drilling site with an Er:YAG laser is easier, especially for new implantologists, because the laser beam cannot slip and cause iatrogenic damage like an implant drill.

The Er:YAG laser is used in special indications relating to the implant bed preparation, such as when the bone is very thin and soft. It is beneficial to prepare the implant bed with a laser to disinfect the site, remove the smear layer, activate osteoblastic activity and achieve more bone-to-implant contact during the early healing [31].

Uncovering the implant with the Er:YAG laser leads to fast healing, thus facilitating rapid prosthetic rehabilitation, and is patient-friendly [32]. The combination of longer and shorter Er:YAG pulses for this procedure ensures that the impressions can be taken without a delay.

The most efficient usage of the TwinLight treatment concept in implantology is in the case of peri-implantitis. With Er:YAG, used safely with water irrigation [33] it is possible to clean the granulation tissues both on the bone surface and implant surface while decontaminating [34]. The Nd:YAG laser adds the effect of deep disinfection and biomodulation. Similar to the cleaning of the surgical area after extractions, it is possible to leave the highly fragile surrounding bone intact, because there is no mechanical or chemical trauma while removing the granulation tissue around the implant.

## LASER-ASSISTED AESTHETIC DENTISTRY

In the field of aesthetic dentistry there are many procedures where a laser is the treatment method of choice. Crown lengthening or gingival leveling (Figure 5) can be a routine procedure for laser-assisted aesthetic interventions [35]. When Er:YAG is used, almost no anesthesia is needed as it does not cause thermal damage to the tissue. The result is a stable gingival height after the procedure. When required, the bone level may be corrected with an Er:YAG laser equipped with adjustable pulse duration (referred to as VSP technology in Fotona lasers) in a non-invasive way without raising a flap [36].

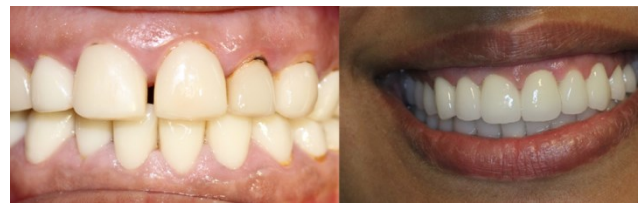


Fig. 5: Crown lengthening before treatment (a). Crown lengthening 6 months after treatment (b).

During prosthetic work, the Nd:YAG laser is very helpful for troughing before taking impressions or desensitizing prepared teeth if required. It is also advisable to reduce or eliminate dentin hypersensitivity due to periodontal treatment or gingival recession by either modulating the nerve endings or blocking the dentinal tubules with the use of a laser.

The treatment of gingival depigmentation [37] (Figure 6) is very safe with the Er:YAG laser due to its superficial absorption. De-epithelisation of the basal layer with pigmentation is achieved with longer Er:YAG pulses. If a small amount of water spray is used, there can be mild bleeding during the operation, but the tissue heals faster.

Aesthetic class V cavity restorations require precise preparations for composite fillings, which are easily performed with an Er:YAG laser. The treatment is quick, painless, and without any thermal side effects, especially if the pulse durations are short enough – typically between 50-100 microseconds. Borders of the cavity can even be beveled for better aesthetic appearance and long-term color stability if the laser is efficient enough to remove small amounts of sound enamel when needed. When the gingival borders of the carious lesion need to be uncovered, the Er:YAG laser with pulse durations between 600-1000 microseconds (Figure 7) is a perfect tool, as there is no blood and generally no anesthesia is required.

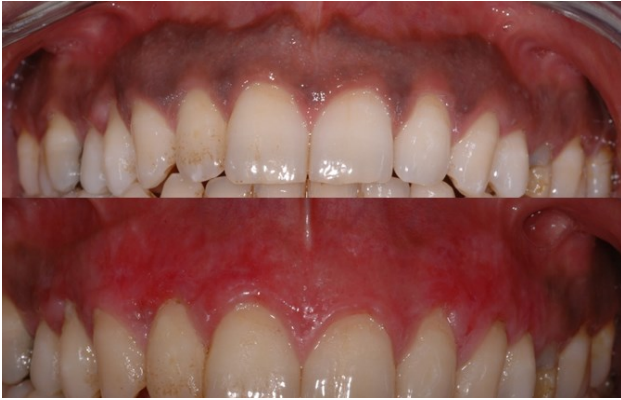

Fig. 6: Gingival depigmentation before treatment(a). Gingival depigmentation 7days after treatment (b).

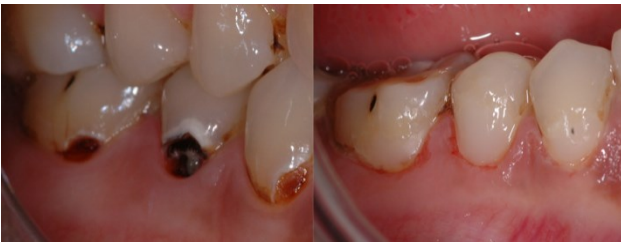

Fig. 7: Clinical case before treatment (a). Immediately after gingivectomy and carious lesion removal.

The activation of the bleaching gel (Figure 8) for tooth whitening is very successful with the help of the Er:YAG laser [38,39] with very long pulses. The procedure is patented and known as the TouchWhite™ procedure. The overall treatment time as well as post-operative sensitivity is decreased.

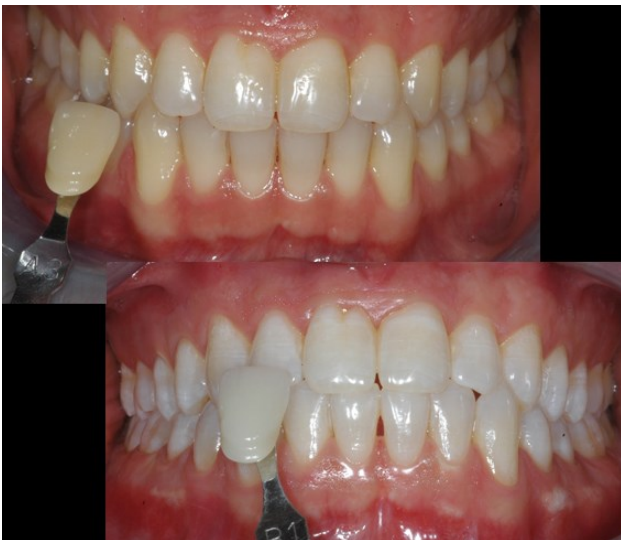

Fig. 8: Before (a) and after (b) TouchWhite™ procedure.

The Nd:YAG laser can also be used for the treatment of herpetic lesions (Figure 9). The advantages of treating a herpetic lesion by laser are that the pain is relieved shortly after lasing, the lesion is healed faster and reoccurrence is less frequent at the treated area.

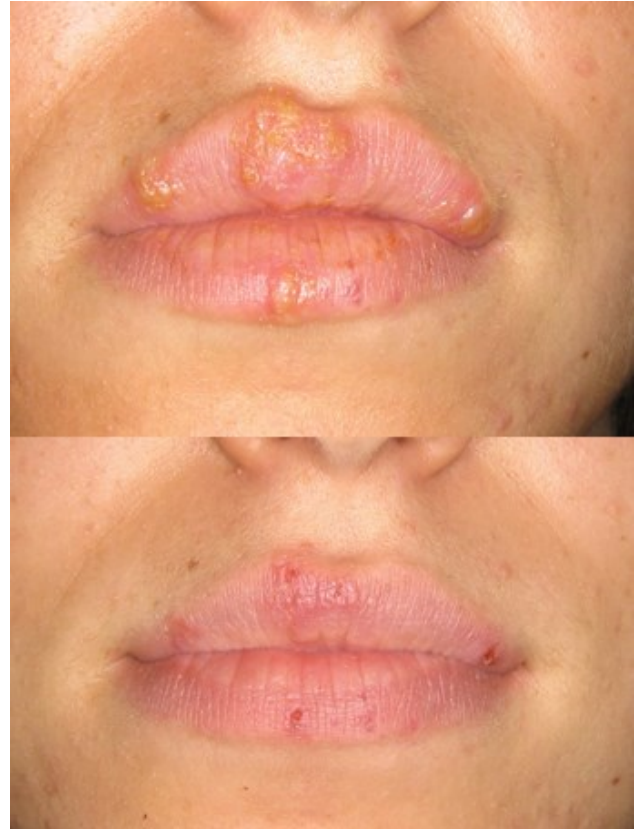

Fig. 9: Before (a) and 4 days after (b) treatment of herpetic lesions.

There are aesthetic reasons for many soft-tissue procedures in the anterior area, like removal of hemangioma [40] or overgrown tissues [41]. It is essential to be certain about the nature of the tissue that is being removed. Non-invasive treatment of hemangioma is performed with the Nd:YAG laser. Its energy is strongly absorbed in hemoglobin, the lesion is coagulated, and it is either left to be removed by mast cells or ablated. The Er:YAG laser is preferred for soft-tissue surgeries like removal of overgrown tissues [27] (Figure 10). The treatment is fast, requires minimum anesthesia and does not cause a delay in healing. In soft-tissue surgeries it is important to increase the Er:YAG pulse duration above 600 microseconds, preferably up to 1000, to raise the quantity of heat delivered – still without damaging the tissue – and provide hemostasis. If necessary, an additional effect of hemostasis can be provided with the Nd:YAG laser. The biomodulation effect of Nd:YAG lasers [42] is also advantageous, helping to increase cell turn-over and blood circulation (with an anti-inflammatory effect), eliminate pain, improve nerve transmission and myorelaxation, stimulate the release of growth hormones, as well as improve many more aspects of healing.



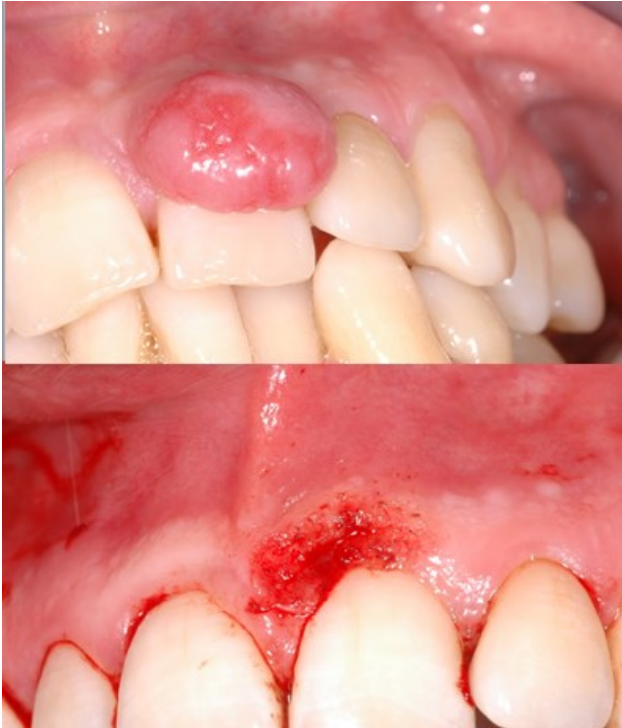

Fig. 10: Before removal of overgrown tissues (a) and immediately after the removal with an erbium laser (b).

## CONCLUSION

The many benefits of using two wavelengths in practically every field of dentistry improve the quality of dental treatments, increase the comfort of the patient and give dentists more reasons to enjoy their profession. Most dentists appreciate when they can use both wavelengths with only one instrument, like with the LightWalker system produced by Fotona. It is essential, however, to obtain an adequate education of both the biophysical interactions underlying the treatment protocols and the specific properties of each laser wavelength and device.

## REFERENCES

1. Frenzen R. Principles of Medical and Dental Lasers. Lulu publishing, 2011.
2. Suen JY, Waner M. Treatment of oral cavity vascular malformations using the neodymium:YAG laser. Arch Otolaryngol Head Neck Surg. 1989 Nov; 115(11):1329-33.
3. Bergmans L, Moisiadis P, Teughels W, Van Meerbeek B, Quirynen M, Lambrechts P. Bactericidal effect of Nd:YAG laser irradiation on some endodontic pathogens ex vivo. Int Endod J. 2006 Jul; 39(7):547-57.
4. Simunovic K, Scholtz A. Laser-assisted dentistry in the daily office routine: A "multi-wave" concept. International Magazine of Laser Dentistry, Vol. 3, Issue 4/2011: 16-21.
5. Vescovi P, Manfredi M, Merigo E, Meleti M, Fornaini C, Rocca JP, Nammour S. Surgical approach with Er:YAG laser on osteonecrosis of the jaws (ONJ) in patients under bisphosphonate therapy (BPT). Laser Med Sci (2010) 25:101-113.
6. Peters OA, Bardsley S, Fong J, Pandher G, DiVito E. Disinfection of Root Canals with Photon-initiated Photoacoustic Streaming. Journal of Endodontics Volume 37, Issue 7, Pages 1008-1012, July 2011.

7. DiVito E, Peters OA, Olivi G. Effectiveness of the erbium:YAG laser and new design radial and stripped tips in removing the smear layer after root canal instrumentation. Lasers Med Sci. 2012;27:273-280. Ando Y, Aoki A, Watanabe H, Ishikawa I. Bactericidal effect of erbium YAG laser on periodontopathic bacteria. Lasers Surg Med 1996; 19: 190-200.
8. Yamaguchi H, Kobayashi K, Osada R, Sakuraba E, Nomura T, Arai T, Nakamura J. Effects of irradiation of an erbium:YAG laser on root surfaces. J Periodontol 1997; 68: 1151-1155.
9. Simunovic K. TwinLight™ laser-assisted endodontics, International Magazine of Laser Dentistry, Vol. 3, Issue 2/2011: 32-34.
10. Aoki A, Miura M, Akiyama F, Nakagawa N, Tanaka J, Oda S, Watanabe H, Ishikawa I. In vitro evaluation of Er:YAG laser scaling of subgingival calculus in comparison with ultrasonic scaling. J Periodontal Res 2000; 35: 266-277.
11. Folwaczny M, Mehl A, Aggastaller H, Hickel R. Antimicrobial effects of 2.94 micron Er:YAG laser radiation on root surfaces: an in vitro study. J Clin Periodontol 2002; 29: 73-78.
12. Akiyama, F., Aoki, A., Miura-Uchiyama, M., Sasaki, K. M., Ichinose, S., Umeda, M., Ishikawa, I., et al (2011). In vitro studies of the ablation mechanism of periodontopathic bacteria and decontamination effect on periodontally diseased root surfaces by erbium:yttrium-aluminum-garnet laser Lasers in Medical Science, 26(2), 193-204.
13. Folwaczny, M., Aggastaller, H., Mehl, A., & Hickel, R (2003). Removal of bacterial endotoxin from root surface with Er:YAG laser American journal of dentistry, 16(1), 3-5.
14. Schultz RJ, Harvey GP, Fernandez-Beros ME, Krishnamurthy S, Rodriguez JE, Cabello F (1986) Bactericidal effects of the Neodymium:YAG laser: in vitro study. Lasers in Surgery and Medicine 6(5):445-8.
15. Rooney J, Midda M, Leeming J (1994) A laboratory investigation of the bactericidal effect of a Nd:YAG laser. British Dental Journal 176(2):61-4.
16. Meral G, Tasar F, Kocagöz S, Sener C (2003) Factors affecting the antibacterial effects of Nd:YAG laser in vivo. Lasers in Surgery and Medicine 32(3):197-202.
17. Harris DM, Yessik M (2004) Therapeutic ratio quantifies laser antiseptics: ablation of Porphyromonas gingivalis with dental lasers. Lasers in Surgery and Medicine 35(3):206-13.
18. Bolortuya, G., Ebihara, A., Ichinose, S., Watanabe, S., Anjo, T., Kokuzawa, C., Saegusa, H., et al (2012). Effects of dentin surface modifications treated with Er:YAG and Nd:YAG laser irradiation on fibroblast cell adhesion Photomedicine and Laser Surgery, 30(2), 63-70.
19. Schwarz, F., Sculean, A., Georg, T., & Reich, E (2001). Periodontal treatment with an Er:YAG laser compared to scaling and root planing. A controlled clinical study Journal of Periodontology, 72(3), 361-7.
20. Schwarz, F., Sculean, A., Berakdar, M., Georg, T., Reich, E., & Becker, J (2003). Periodontal treatment with an Er:YAG laser or scaling and root planing. A 2-year follow-up split-mouth study Journal of Periodontology, 74(5), 590-6. doi:10.1902/jop.2003.74.5.590.
21. Badran, Z., Boutigny, H., Struillou, X., Weiss, P., Laboux, O., & Soueidan, A (2012). Clinical Outcomes After Nonsurgical Periodontal Therapy with an Er:YAG Laser Device: A Randomized Controlled Pilot Study Photomedicine and Laser Surgery, 30(7), 347-53.
22. Lopes, B. M., Theodoro, L. H., Melo, R. F., de Thompson, G. M., & Marcantonio, R. A (2010). Clinical and microbiologic follow-up evaluations after non-surgical periodontal treatment with erbium:YAG laser and scaling and root planing Journal of Periodontology, 81(5), 682-91.
23. Domínguez, A., Gómez, C., García-Kass, A. I., & García-Núñez, J. A (2010). IL-1beta, TNF-alpha, total antioxidant status and microbiological findings in chronic periodontitis treated with fluorescence-controlled Er:YAG laser radiation Lasers in Surgery and Medicine, 42(1), 24-31.
24. Tomasi, C., Schander, K., Dahlén, G., & Wennström, J. L (2006). Short-term clinical and microbiologic effects of pocket debridement with an Er:YAG laser during periodontal maintenance Journal of Periodontology, 77(1), 111-8.

25. Crespi, R., Capparè, P., Toscanelli, I., Gherlone, E., & Romanos, G. E (2007). Effects of Er:YAG laser compared to ultrasonic scaler in periodontal treatment: a 2-year follow-up split-mouth clinical study *Journal of Periodontology*, 78(7), 1195-200.
26. Braun, A., Jepsen, S., Deimling, D., & Ratka-Krüger, P (2010). Subjective intensity of pain during supportive periodontal treatment using a sonic scaler or an Er:YAG laser *Journal of Clinical Periodontology*, 37(4), 340-5.
27. Ishikawa I, Aoki A, Takasaki AA. Potential applications of Erbium:YAG laser in periodontics. *J Periodontal Res*. 2004 Aug;39(4):275-85.].
28. Romanos GE, Gutknecht N, Dieter S, Schwarz F, Crespi R, Sculean A. Laser wavelengths and oral implantology. *Lasers Med Sci*. 2009 Nov;24(6):961-70
29. Maden I, Kazak Z. Lasers in oral implantology, *International Magazine of Laser Dentistry*, Vol. 4, Issue 2/2012: 34-36.
30. Pourzarandian A, Watanabe H, Aoki A, Ichinose S, Sasaki KM, Nitta H, Ishikawa I. Histological and TEM examination of early stages of bone healing after Er:YAG laser irradiation. *Photomed Laser Surg*. 2004 Aug;22(4):342-50.
31. Kesler G, Romanos G, Koren R. Use of Er:YAG laser to improve osseointegration of titanium alloy implants—a comparison of bone healing. *Int J Oral Maxillofac Implants*. 2006 May-Jun;21(3):375-9.
32. Arnabat-Domínguez J, España-Tost AJ, Berini-Aytés L, Gay-Escoda C. Erbium:YAG laser application in the second phase of implant surgery: a pilot study in 20 patients. *Int J Oral Maxillofac Implants*. 2003 Jan-Feb;18(1):104-12.
33. Leja C, Geminiani A, Caton J, Romanos GE. Thermodynamic effects of laser irradiation of implants placed in bone: an in vitro study. *Lasers Med Sci*. 2012 Oct 10. [Epub ahead of print].
34. Kim JH, Herr Y, Chung JH, Shin SI, Kwon YH. The effect of erbium-doped: yttrium, aluminium and garnet laser irradiation on the surface microstructure and roughness of double acid-etched implants. *J Periodontal Implant Sci*. 2011 Oct;41(5):234-41.
35. Maden I, Kazak Z, Erbil Maden O. Lasers in aesthetic dentistry, *Cosmetic Dentistry*, Vol. 7, Issue 1/2013: 30-32.
36. McGuire MK, Scheyer ET. Laser-assisted flapless crown lengthening: a case series. *Int J Periodontics Restorative Dent*. 2011 Jul-Aug;31(4):357-64.
37. Hegde R, Padhye A, Sumanth S, Jain AS, Thukral N. Comparison of Surgical Stripping, Er:YAG Laser and CO(2) Laser Techniques for Gingival Depigmentation: A Clinical & Histological Study. *J Periodontol*. 2012 Sep 24].
38. Gutknecht N, Franzen R, Meister J, Lukac M, Pirnat S, Zabkar J, Cencic B, Jovanovic J. A Novel Er:YAG Laser-Assisted Tooth Whitening Method *Journal of the Laser and Health Academy* Vol. 2011, No. 1.
39. Dinc AT, Maden OE. Laser Tooth Whitening: Diode vs. TouchWhite Er:YAG *Journal of the Laser and Health Academy* Vol. 2012, No. 1.
40. Actis A, Juri H, Gendelman H. Oral Hemangiomas Treated with Nd:YAG and CO2 Laser. *Journal of Clinical Laser Medicine & Surgery* Volume 11, Number 2, 1993.
41. White JM, Chaudhry SI, Kudler JJ, Sekandari N, Schoelch ML, Silverman S Jr. Nd:YAG and CO2 laser therapy of oral mucosal lesions. *J Clin Laser Med Surg*. 1998 Dec;16(6):299-304.
42. Chellini F, Sassoli C, Nosi D, Deledda C, Tonelli P, Zecchi-Orlandini S, Formigli L, Giannelli M. Low pulse energy Nd:YAG laser irradiation exerts a biostimulative effect on different cells of the oral microenvironment: "an in vitro study". *Lasers Surg Med*. 2010 Aug;42(6):527-39.

The intent of this Laser and Health Academy publication is to facilitate an exchange of information on the views, research results, and clinical experiences within the medical laser community. The contents of this publication are the sole responsibility of the authors and may not in any circumstances be regarded as official product information by the medical equipment manufacturers. When in doubt please check with the manufacturers whether a specific product or application has been approved or cleared to be marketed and sold in your country.