

Efficacy of Unloader Bracing in Reducing Symptoms of Knee Osteoarthritis

Roger V. Ostrander, MD, Charles E. Leddon, PhD, Joshua G. Hackel, MD, Christopher P. O'Grady, MD, and Charles A. Roth, MD

Abstract

Braces designed to unload the more diseased compartment of the knee have been used to provide symptomatic relief from osteoarthritis (OA). Research on the efficacy of these braces is needed.

Thirty-one patients with knee OA were randomized to receive an unloader brace ($n = 16$) or not to receive a brace (control group, $n = 15$). Knee Injury and Osteoarthritis Outcomes Score (KOOS) and visual analog scale (VAS) scores were used to evaluate outcomes.

KOOS results showed that the brace group had significantly less pain ($P < .001$), fewer arthritis symptoms ($P = .007$), and better abil-

ity to engage in activities of daily living ($P = .008$). There was no difference in function in sport and recreation ($P = .402$) or in knee-related quality of life ($P = .718$). VAS results showed that the brace group had significantly less pain throughout the day ($P = .021$) and had improved activity levels ($P = .035$). There was no difference in ability to sleep ($P = .117$) or in use of nonsteroidal anti-inflammatory drugs ($P = .138$).

Our study results showed that use of an unloader brace for medial compartment knee OA led to significant improvements in pain, arthritis symptoms, and ability to engage in activities.

Knee osteoarthritis (OA) is a progressive, degenerative joint disease characterized by pain and dysfunction. OA is a leading cause of disability in middle-aged and older adults,¹ affecting an estimated 27 million Americans.² With the continued aging of the baby boomer population and rising obesity rates, the incidence of OA is estimated to increase by 40% by 2025.³ The clinical and economic burdens of OA on our society—medical costs and workdays lost—are significant and will continue to be a problem for years to come.⁴

Total knee arthroplasty (TKA) is an option for severe end-stage OA. Most patients with mild to moderate OA follow nonsurgical strategies in an attempt to avoid invasive procedures. As there is no established cure, initial treatment of knee OA is geared toward alleviating pain and improving function. A multimodal approach is typically used

and recommended.^{5,6} Nonsteroidal anti-inflammatory drugs (NSAIDs), acetaminophen, and narcotic analgesics are commonly prescribed. NSAIDs can be effective⁷ but have well-known cardiovascular, renal, and gastrointestinal risks. If possible, narcotic analgesics should be avoided because of the risk of addiction and the problems associated with dependence. Intra-articular injections of corticosteroids or hyaluronic acid (viscosupplementation) are often recommended to reduce pain associated with arthritis. Braces designed to “off-load” the more diseased medial or lateral compartment of the knee have also been used in an effort to provide symptomatic relief. These low-risk, non-invasive unloader braces have increasingly been advanced as a conservative treatment modality for knee OA,^{6,8-10} despite modest evidence and lack of appropriately powered randomized controlled trials.¹¹ As more research on the efficacy of these

Authors' Disclosure Statement: The authors report that their institution (Andrews Institute) has received research funding from Breg, Inc., which makes the medial unloader brace used in this study. Breg contributed to the study's conception and design but was not involved in collecting, analyzing, or interpreting data, or in writing the manuscript or submitting it for publication.

braces is needed, we conducted a study to determine whether an unloader brace is an acceptable and valid treatment modality for knee OA.

Patients and Methods

This was a prospective, randomized, controlled trial of patients with symptomatic, predominantly unicompartmental OA involving the medial compartment of the knee. The study protocol was approved by the Institutional Review Board at Baptist Hospital in Pensacola, Florida. Patients were excluded if they had a rheumatologic disorder other than OA; a history of knee surgery other than a routine arthroscopic procedure; any soft-tissue, neurologic, or vascular compromise preventing long-term brace use; or obesity preventing effective or comfortable brace use. It is generally felt that unloader bracing may not be effective for patients with severe contractures or significant knee deformity; therefore, those lacking more than 10° of extension or 20° of flexion, or those who had a varus deformity of more than 8° of varus, were not offered enrollment.

Ideal sizes for the proposed study groups were determined through power analysis using standard deviations from prior similar investigations. The target was 30 patients per group.

Patients gave informed consent to the work. A computer-generated randomization schedule was used to randomize patients either to receive a medial unloader brace (Fusion OA; Breg, Inc) or not to receive a brace. Patients in these brace and control groups were allowed to continue their standard conservative OA treatment modalities, including NSAID use, home exercises, and joint supplement use. Patients were restricted from receiving any injection therapy or narcotic pain medication in an effort to isolate the effects of bracing on relief of

pain and other symptoms.

All patients were examined by an orthopedic surgeon or fellowship-trained primary care sports medicine specialist. Age, sex, height, and weight data were recorded. Body mass index was calculated. Anteroposterior, lateral, flexion weight-bearing, and long-leg standing radiographs were obtained. Two orthopedic surgeons blindly graded OA¹² and calculated knee varus angles.¹³ Values were averaged, and intraobserver reliability and interobserver reliability were calculated.

Prospective subjective outcomes were evaluated with the Knee Injury and Osteoarthritis Outcome Score (KOOS), administered on study entry and at 4, 8, 16, and 24 weeks during the study. The KOOS has 5 subscales: Pain, Symptoms, Function in Daily Living, Function in Sport and Recreation, and Knee-Related Quality of Life. Each subscale is scored separately. Items are rated 0 (extreme problems) to 100 (no problems). Patients were also asked to complete a weekly diary, which included visual analog scale (VAS) ratings of pain, NSAID use, sleep, and activity level. VAS items were rated 1 (extreme problems) to 100 (no problems). For brace-group patients, hours of brace use per day were recorded. Patients were required to use the brace for a minimum of 4 hours per day.

KOOS and VAS data were analyzed with repeated-measures analysis of variance. Significance level was set at $P < .05$.

Results

Of the 50 patients randomized, 31 (16 brace, 15 control) completed the study. Of the 19 dropouts, 10 were in the brace group (4 dropped out because of brace discomfort) and 9 in the control group (5 dropped out because of significant pain and the desire for more aggressive treatment with

Table 1. Characteristics of Brace and Control Groups

Characteristic	Brace Group		Control Group		P
	Mean	SD	Mean	SD	
Age, y	63.1	6.3	66.8	9.7	.2132
Height, cm	172.1	13.5	173.7	11.6	.5340
Weight, kg	89.7	24.0	95.6	22.4	.4886
Varus angle, °	2.83	0.632	2.69	.695	.5495
Arthritis grade	5.29	3.30	5.47	2.76	.4396
Body mass index	29.8	4.5	31.5	6.1	.3709

injections). The target patient numbers based on the power analysis were not achieved because of patient enrollment difficulties resulting from the strict criteria established in the study design.

The brace group consisted of 8 men and 8 women. Braces were worn an average of 6.7 hours per day. The control group consisted of 8 men and 7 women. The groups were not significantly different in age, height, weight, body mass index, measured varus knee angle, or arthritis grade (**Table 1**).

Radiographs were assessed by 2 orthopedic surgeons. Varus angle measurements showed high interobserver reliability (.904, $P = .03$) and high intraobserver reliability (.969, $P = .05$); arthritis grades showed low interobserver reliability (.469, $P = .59$) and high intraobserver reliability (.810, $P = .001$).

KOOS results showed that, compared with control patients, brace patients had significantly less pain ($P < .001$), fewer arthritis symptoms ($P = .007$), better ability to engage in activities of daily living (ADLs) ($P = .008$), and better total knee function ($P = .004$) (**Figures 1-4**). The groups did not differ in ability to engage in sport and recreation ($P = .402$) or in knee-related quality of life ($P = .718$), but each parameter showed a trend to be better in the brace group. There was no effect of time in any KOOS subscale. Confidence intervals for these data are listed in **Table 2**.

VAS results showed that, compared with control patients, brace patients had significantly less pain throughout the day ($P = .021$) and better activity levels ($P = .035$) (**Figures 5, 6**). The groups did not differ in ability to sleep ($P = .117$) or NSAID use

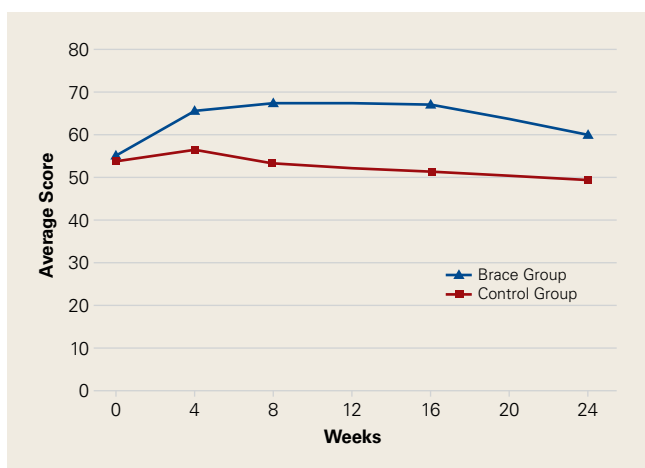


Figure 1. Pain prospectively rated 0 (extreme problems) to 100 (no problems) on Pain subscale of Knee Injury and Osteoarthritis Outcome Score.

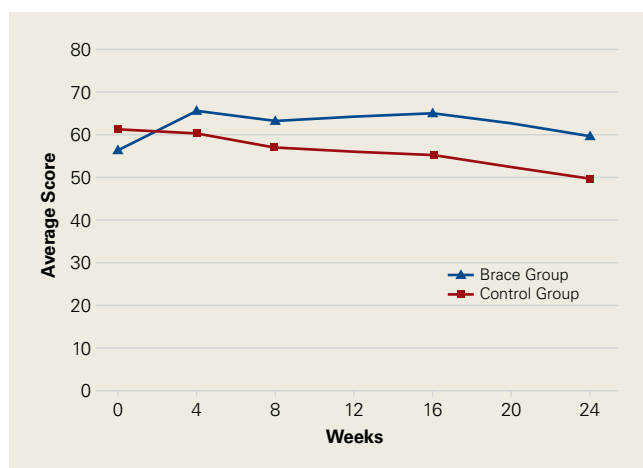


Figure 2. Symptoms other than pain prospectively rated 0 (extreme problems) to 100 (no problems) on Symptoms subscale of Knee Injury and Osteoarthritis Outcome Score.

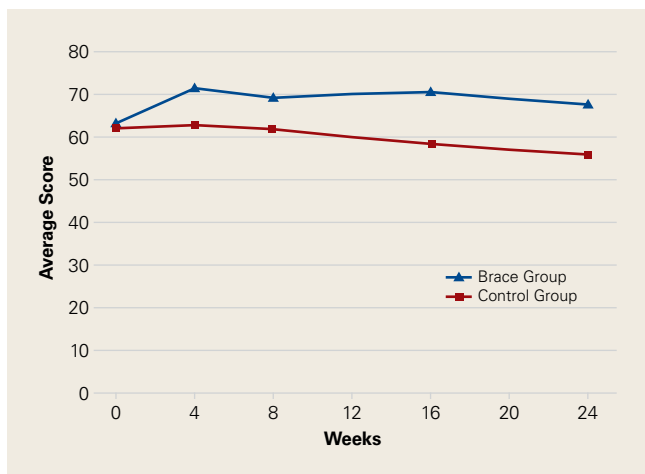


Figure 3. Function in activities of daily living prospectively rated 0 (extreme problems) to 100 (no problems) on Function in Daily Living subscale of Knee Injury and Osteoarthritis Outcome Score.

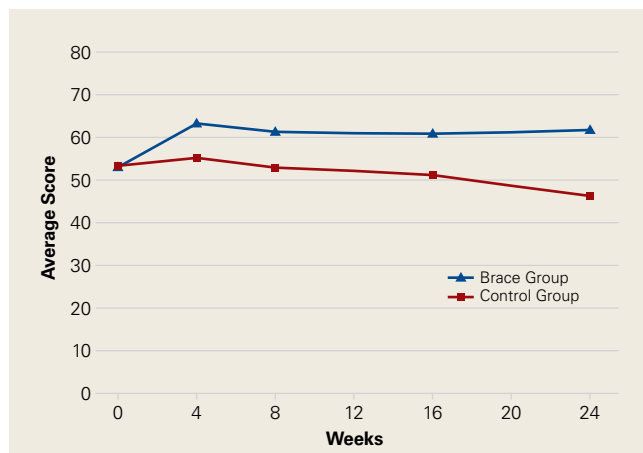


Figure 4. Total knee function prospectively rated 0 (extreme problems) to 100 (no problems) on Knee Injury and Osteoarthritis Outcome Score.

($P = .138$), but each parameter showed a trend to be better in the brace group. There was no effect of time in either VAS.

Discussion

We conducted this study to determine the efficacy of a medial unloader brace in reducing the pain and symptoms associated with varus knee OA.

Although TKA is an option for patients with significant end-stage knee OA, mild OA and moderate OA typically are managed with nonoperative modalities. These modalities can be effective and may delay or eliminate the need for surgery, which poses a small but definite risk. Delaying surgery, especially in younger, active patients, has the potential to reduce the number of wear-related revision surgeries.¹⁴

Braces designed to off-load the more diseased medial or lateral compartment of the knee have been used in an effort to provide relief from

symptomatic OA. There is a lack of appropriately powered, randomized controlled studies on the efficacy of these braces. With the evidence being inconclusive, the American Academy of Orthopaedic Surgeons is unable to recommend for or against use of a brace in medial unicompartmental OA.¹¹ More research on the efficacy of these braces is needed. In the present study, we asked 2 questions: Does use of an unloader brace lessen the pain associated with knee OA? Is the unloader brace an acceptable and valid treatment modality for knee OA?

The 2 clinical outcome tools used in this study showed significant improvement in pain in brace patients compared with control patients. KOOS results showed reduced pain and arthritis symptoms. VAS results showed less pain experienced throughout the day. Pain reduction is probably the most important benefit of any nonoperative modality for knee OA. Pain typically is the driving force

Table 2. Confidence Intervals for Knee Injury and Osteoarthritis Outcome Score Subscales

Subscale	Confidence Interval	
	Brace Group	Control Group
Pain	59.5-66.9	49.2-56.8
Symptoms	58.0-66.2	52.5-61.0
Function in Daily Living	64.2-72.6	55.8-64.5
Function in Sport and Recreation	30.1-43.7	25.1-40.1
Knee-Related Quality of Life	30.8-41.2	29.4-40.0
Total	56.2-64.0	47.9-55.8

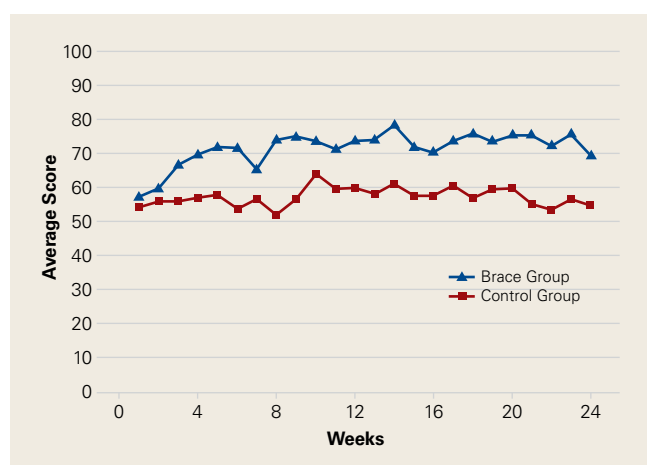


Figure 5. Pain prospectively rated 1 (extreme problems) to 100 (no problems) on visual analog scale.

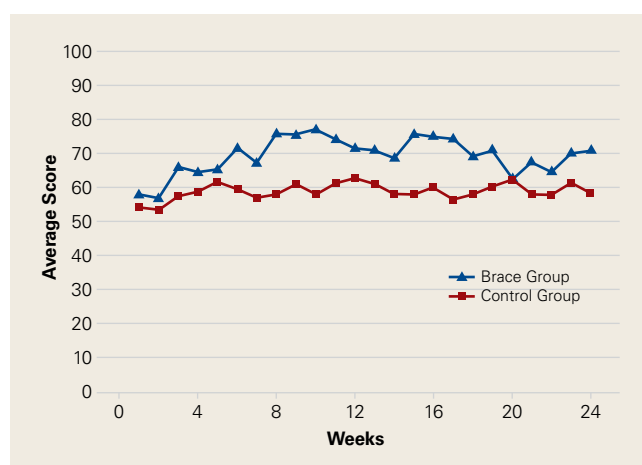


Figure 6. Activity level prospectively rated 1 (extreme problems) to 100 (no problems) on visual analog scale.

and the major indication for TKA. Other investigators have found pain reduced with use of unloader braces, but few long-term prospective randomized trials have been conducted. Ramsey and colleagues¹⁵ compared a neutral stabilizing brace with a medial unloading brace and found that both helped reduce pain and functional disability. This led to discussion about the 2 major potential mechanisms for symptom relief. One theory holds that bracing unloads the diseased portion of the joint and thereby helps improve symptoms.¹⁶⁻¹⁸ According to the other theory, bracing stabilizes the knee, reducing muscle cocontractions and joint compression.^{15,19,20} Draganich and colleagues²¹ found that both off-the-shelf and adjustable unloader braces reduced pain. In a short-term (8-week) study, Barnes and colleagues²² found substantial improvement in knee pain with use of an unloader brace. In one of the larger, better designed, prospective studies, Brouwer and colleagues²³ found borderline but significant improvements in pain. Larsen and colleagues,²⁴ in another short-term study, found no improvement in pain but did report improved activity levels with use of a medial unloader brace.

In addition to demonstrating pain reduction, our results showed that, compared with control patients, brace patients had fewer arthritis symptoms, better ability to engage in ADLs, and increased activity levels. Other studies have identified additional benefits of bracing for knee arthritis. Larsen and colleagues²⁴ found that valgus bracing for medial compartment knee OA improved walking and sit-to-stand activities. Although pain relief results were modest, Brouwer and colleagues²³ found significantly better knee function and longer walking distances for patients who used a medial unloader brace. Hewett and colleagues²⁵ found that pain, ADLs, and walking distance were all improved after 9 weeks of brace wear.

Our study had a few limitations. Although injections and narcotic pain medications were not allowed, NSAIDs, home exercises, and other modalities were permitted. We did not think it was reasonable to eliminate every nonoperative modality during the 6-month study period. Therefore, it is possible that some of the study population's improvements are attributable to these other modalities, which were not rigidly controlled.

Patient enrollment was difficult because of the strict inclusion and exclusion criteria used. The result was a smaller than anticipated patient population. Although there were many excellent study candidates, most declined enrollment when they

learned they could be randomized to the control group. These patients were not willing to forgo injections or bracing for 6 months. We thought it was important to maintain our study design because it allowed us to evaluate the true effect of brace use while eliminating confounding variables. Nearly equal numbers of brace and control patients dropped out of the study. The majority of control group dropouts wanted more treatment options, indicating that NSAIDs and exercises alone were not controlling patients' symptoms. This finding supports recommendations for a multimodal approach to treatment. As expected, some patients dropped out because their brace was uncomfortable—an important finding that should be considered when counseling patients about treatment options for OA.

Not all patients are candidates for braces. Braces can be irritating and uncomfortable for obese patients and patients with skin or vascular issues. Some patients find braces inconvenient. As discussed, a multimodal OA treatment approach is encouraged, but not every mode fits every patient. Physician and patient should thoroughly discuss the benefits and potential problems of brace use before prescribing. Our study results showed trends toward better improvements for brace patients (compared with control patients) in quality of life, ability to engage in sport and recreation, ability to sleep, and need for NSAIDs. Had we enrolled more patients, we might have found statistical significance for these trends. Despite the challenges with patient enrollment and study population size, the data make clear that unloader braces can benefit appropriate patients.

Our findings support use of a medial unloader brace as an acceptable and valid treatment modality for mild and moderate knee OA. The medial unloader brace should be considered a reasonable alternative, as part of a multimodal approach, to more invasive options, such as TKA.

Dr. Ostrander is an Orthopaedic Surgeon and Associate Fellowship Director, Sports Medicine and Arthroscopy, Andrews Institute, Gulf Breeze, Florida; Clinical Assistant Professor, Florida State University College of Medicine, Pensacola, Florida; Associate Faculty, Health, Leisure, and Exercise Science Program, University of West Florida, Pensacola, Florida; and Adjunct Assistant Professor, Department of Orthopaedic Surgery, University of South Alabama, Mobile, Alabama. Dr. Leddon is a Sports Medicine Research Associate. Dr. Hackel is Director of Primary Care Sports Medicine Fellowship, and Dr. O'Grady and Dr. Roth are Orthopaedic Surgeons and Fellowship Instructors, Andrews Institute, Gulf Breeze, Florida.

Address correspondence to: Roger V. Ostrander, MD, Andrews Institute, 1040 Gulf Breeze Pkwy, Suite 200, Gulf Breeze, FL 32561 (tel, 850-916-3700; email, rostrander@andrewsortho.com).

Am J Orthop. 2016;45(5):306-311. Copyright Frontline Medical Communications Inc. 2016. All rights reserved.

References

1. Michaud C, McKenna M, Begg S, et al. The burden of disease and injury in the United States 1996. *Popul Health Metr.* 2006;4:11.
2. Lawrence RC, Felson DT, Helmick CG, et al; National Arthritis Data Workgroup. Estimates of the prevalence of arthritis and other rheumatic conditions in the United States. Part II. *Arthritis Rheum.* 2008;58(1):26-35.
3. Woolf AD, Pfleger B. Burden of major musculoskeletal conditions. *Bull World Health Organ.* 2003;81(9):646-656.
4. London NJ, Miller LE, Block JE. Clinical and economic consequences of the treatment gap in knee osteoarthritis management. *Med Hypotheses.* 2011;76(6):887-892.
5. Hochberg MC, Altman RD, April KT, et al; American College of Rheumatology. American College of Rheumatology 2012 recommendations for the use of nonpharmacologic and pharmacologic therapies in osteoarthritis of the hand, hip, and knee. *Arthritis Care Res.* 2012;64(4):465-474.
6. McAlindon TE, Bannuru RR, Sullivan MC, et al. OARS guidelines for the non-surgical management of knee osteoarthritis. *Osteoarthritis Cartilage.* 2014;22(3):363-388.
7. Gallelli L, Galasso O, Falcone D, et al. The effects of nonsteroidal anti-inflammatory drugs on clinical outcomes, synovial fluid cytokine concentration and signal transduction pathways in knee osteoarthritis. A randomized open label trial. *Osteoarthritis Cartilage.* 2013;21(9):1400-1408.
8. Pollo FE, Jackson RW. Knee bracing for unicompartmental osteoarthritis. *J Am Acad Orthop Surg.* 2006;14(1):5-11.
9. Ramsey DK, Russell ME. Unloader braces for medial compartment knee osteoarthritis: implications on mediating progression. *Sports Health.* 2009;1(5):416-426.
10. Zhang W, Moskowitz RV, Nuki G, et al. OARS recommendations for the management of hip and knee osteoarthritis, part II: OARS evidence-based, expert consensus guidelines. *Osteoarthritis Cartilage.* 2008;16(2):137-162.
11. Richmond J, Hunter D, Irrgang J, et al; American Academy of Orthopaedic Surgeons. American Academy of Orthopaedic Surgeons clinical practice guideline on the treatment of osteoarthritis (OA) of the knee. *J Bone Joint Surg Am.* 2010;92(4):990-993.
12. Kellgren JH, Lawrence JS. Radiological assessment of osteo-arthrosis. *Ann Rheum Dis.* 1957;16(4):494-502.
13. Dugdale TW, Noyes FR, Styer D. Preoperative planning for high tibial osteotomy. The effect of lateral tibiofemoral separation and tibiofemoral length. *Clin Orthop Relat Res.* 1992;(274):248-264.
14. Weinstein AM, Rome BN, Reichmann WM, et al. Estimating the burden of total knee replacement in the United States. *J Bone Joint Surg Am.* 2013;95(5):385-392.
15. Ramsey DK, Briem K, Axe MJ, Snyder-Mackler L. A mechanical theory for the effectiveness of bracing for medial compartment osteoarthritis of the knee. *J Bone Joint Surg Am.* 2007;89(11):2398-2407.
16. Haim A, Wolf A, Rubin G, Genis Y, Khoury M, Rozen N. Effect of center of pressure modulation on knee adduction moment in medial compartment knee osteoarthritis. *J Orthop Res.* 2011;29(11):1668-1674.
17. Pollo FE, Otis JC, Backus SI, Warren RF, Wickiewicz TL. Reduction of medial compartment loads with valgus bracing of the osteoarthritic knee. *Am J Sports Med.* 2002;30(3):414-421.
18. Shelburne KB, Torry MR, Steadman JR, Pandy MG. Effects of foot orthoses and valgus bracing on the knee adduction moment and medial joint load during gait. *Clin Biomech.* 2008;23(6):814-821.
19. Lewek MD, Ramsey DK, Snyder-Mackler L, Rudolph KS. Knee stabilization in patients with medial compartment knee osteoarthritis. *Arthritis Rheum.* 2005;52(9):2845-2853.
20. Lewek MD, Rudolph KS, Snyder-Mackler L. Control of frontal plane knee laxity during gait in patients with medial compartment knee osteoarthritis. *Osteoarthritis Cartilage.* 2004;12(9):745-751.
21. Draganich L, Reider B, Rimington T, Piotrowski G, Mallik K, Nasson S. The effectiveness of self-adjustable custom and off-the-shelf bracing in the treatment of varus gonarthrosis. *J Bone Joint Surg Am.* 2006;88(12):2645-2652.
22. Barnes CL, Cawley PV, Hederman B. Effect of CounterForce brace on symptomatic relief in a group of patients with symptomatic unicompartmental osteoarthritis: a prospective 2-year investigation. *Am J Orthop.* 2002;31(7):396-401.
23. Brouwer RV, van Raaij TM, Verhaar JA, Coene LN, Bierma-Zeinstra SM. Brace treatment for osteoarthritis of the knee: a prospective randomized multi-centre trial. *Osteoarthritis Cartilage.* 2006;14(8):777-783.
24. Larsen BL, Jacofsky MC, Brown JA, Jacofsky DJ. Valgus bracing affords short-term treatment solution across walking and sit-to-stand activities. *J Arthroplasty.* 2013;28(5):792-797.
25. Hewett TE, Noyes FR, Barber-Westin SD, Heckmann TP. Decrease in knee joint pain and increase in function in patients with medial compartment arthrosis: a prospective analysis of valgus bracing. *Orthopedics.* 1998;21(2):131-138.